بسم الله الرحمن الرحیم

IMAGING OF MASS LESIONS OF PITUTARY GLAND

DR ARASH KHAMENEH BAGHERI

ASSISSTANT PROFESSOR OF INTERVENTIONAL RADIOLOGY

SHAHID BEHESHTI UNIVERSITY OF MEDICAL SCIENCES

NORMAL PITUITARY GLAND ANATOMY

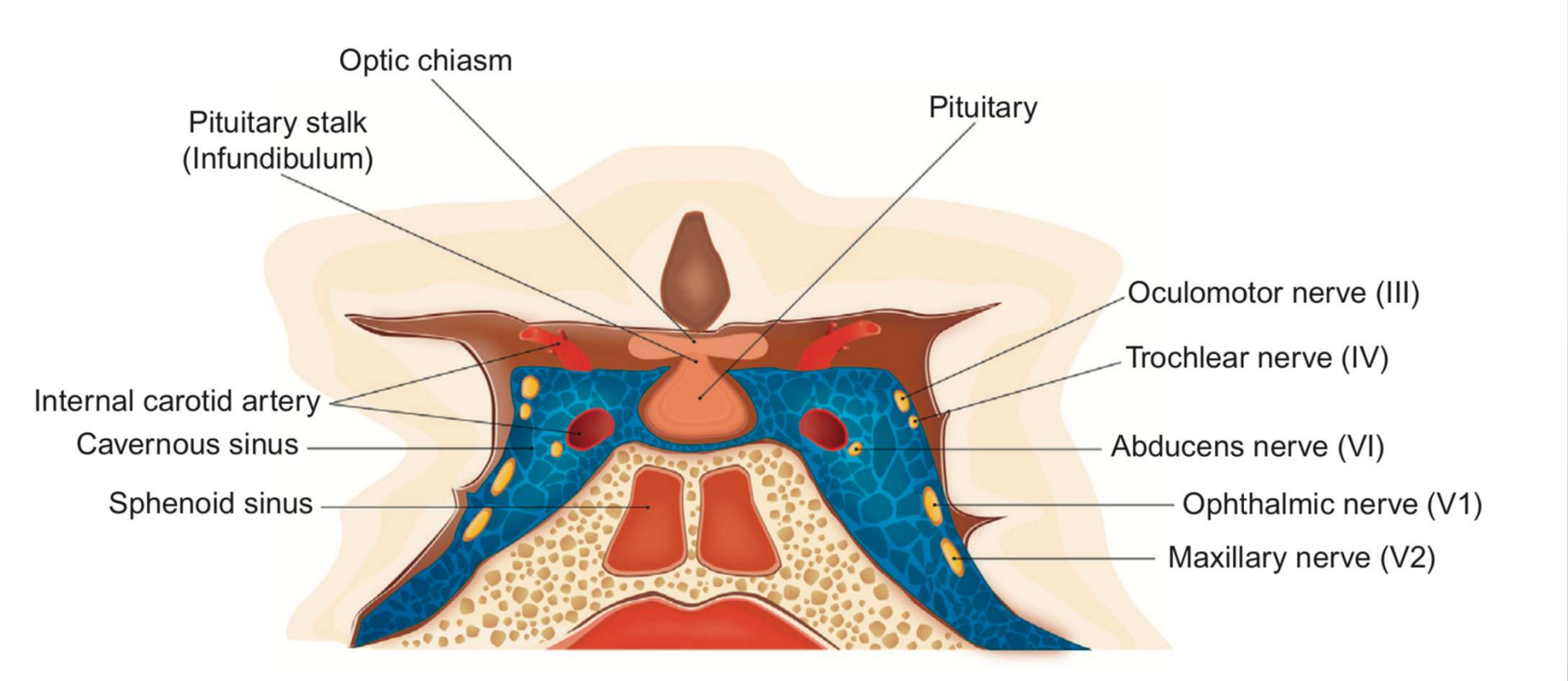

MRI INTERPRETATION

- The first step in interpreting MR imaging is to correctly identify T1- and T2-weighted
- After distinguishing T1- and T2-weighted images, the next step is to identify the pre- and postcontrast T1-weighted images. For physicians with less familiarity with pituitary imaging, looking at the nasal conchae is an easy way to differentiate between pre- and postcontrast images. In pre-contrast images ,the nasal conchae have intensity similar to the brain gray matter (isointense); however, on postcontrast images ,the nasal conchae appear brighter than the gray matter (hyperintense).

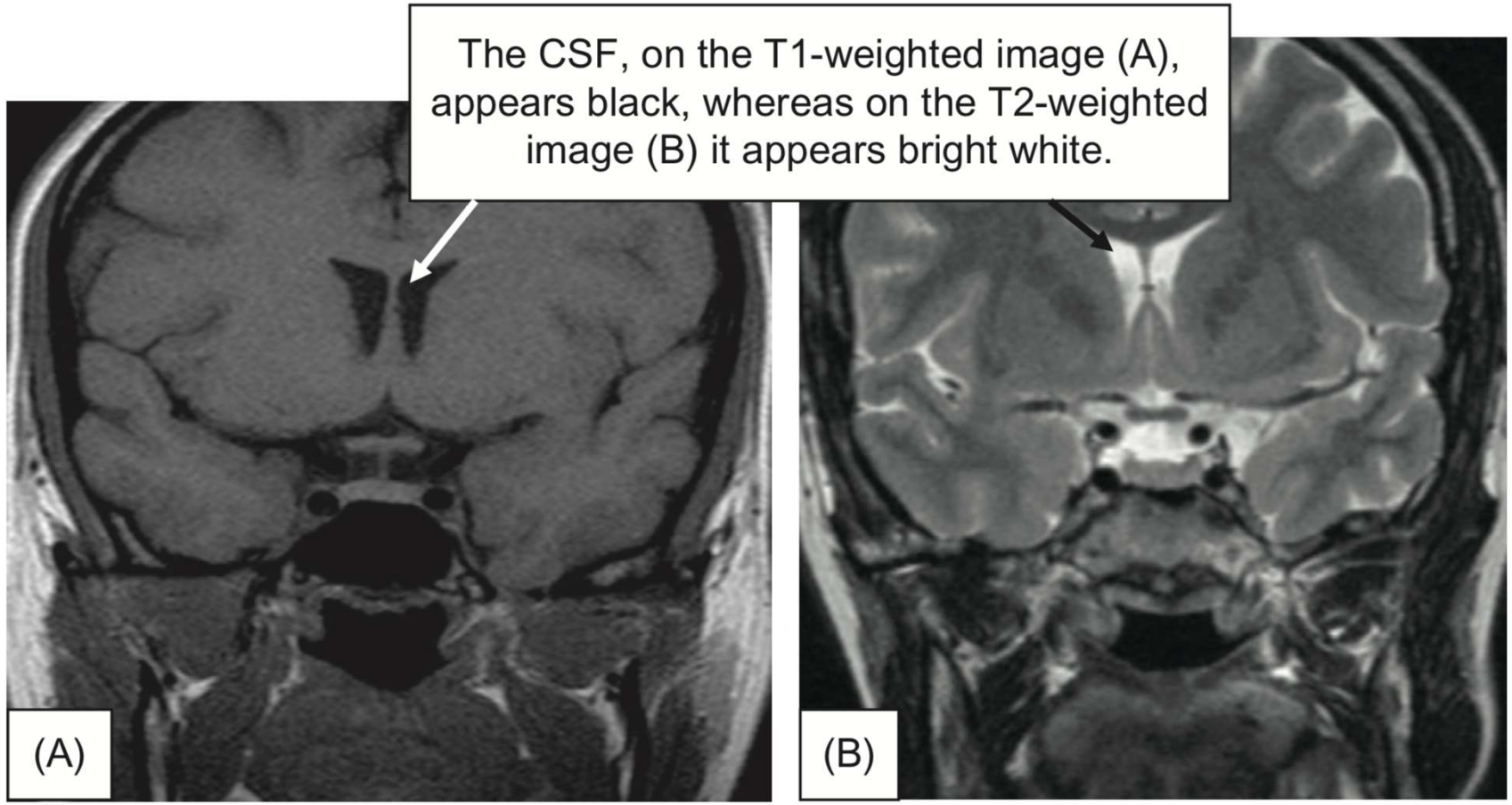

FIGURE 1.2 (A) Coronal T1-weighted image without contrast, and (B) coronal T2-weighted image.

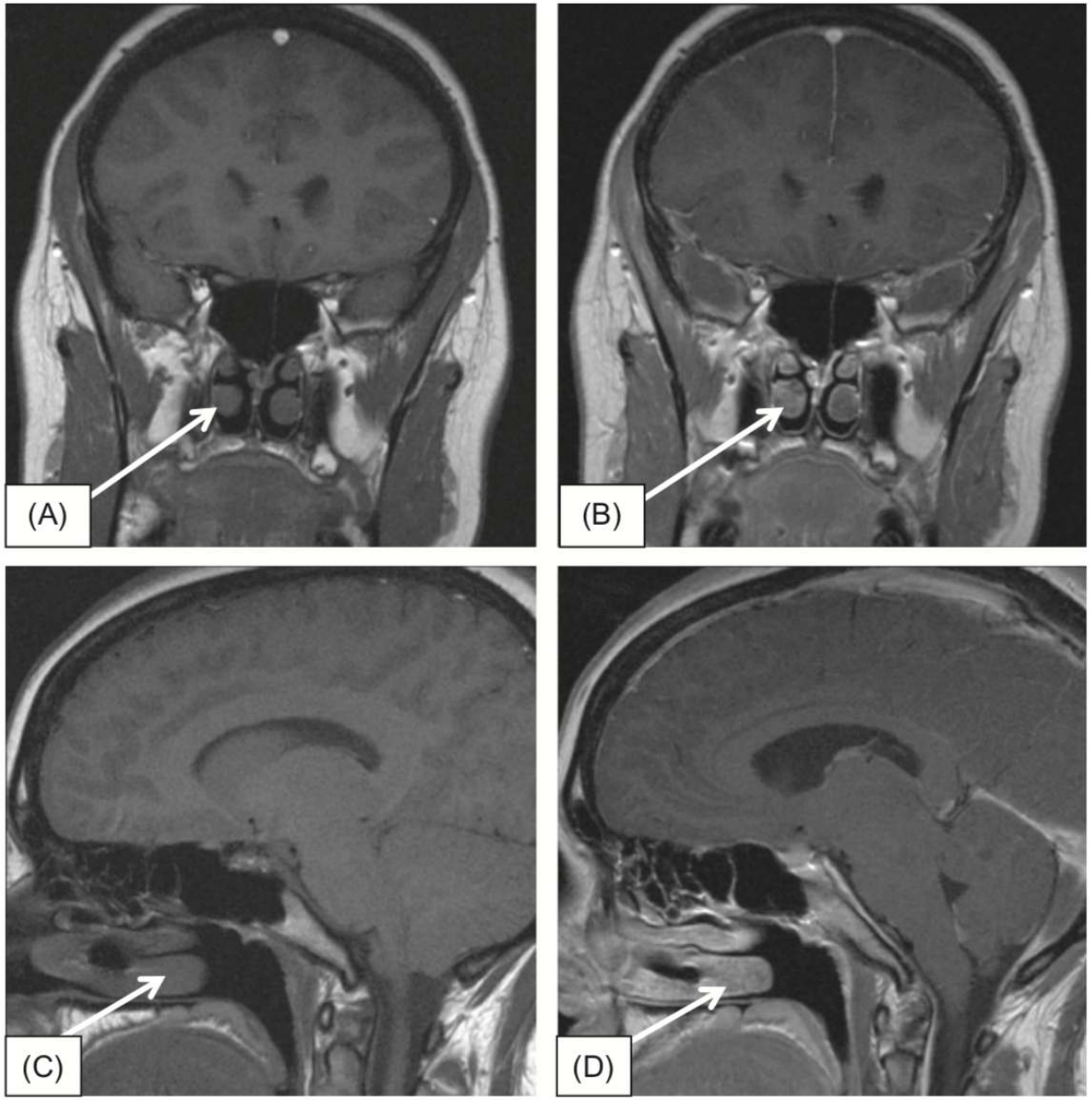

FIGURE 1.3 (A) T1-weighted coronal image precontrast, (B) T1-weighted coronal image postcontrast, (C) T1-weighted sagittal image precontrast, and (D) T1-weighted sagittal image postcontrast.

Normal Pituitary Gland and Sella Anatomy on MRI

- The pituitary stalk typically is less than 4 mm in width . A stalk thickness greater than 4 mm is usually considered pathologic, which needs to be evaluated in the context of the clinical picture.
- On average, the pituitary is 38 mm in size (height), and is generally larger in females than in males.
- In both sexes, the maximum pituitary gland height is usually observed in those within the 20- to 29-year age group.
- In almost all men, the pituitary height is less than 7 mm, and in women it is less than 8 mm.

Normal Pituitary Gland and Sella Anatomy on MRI

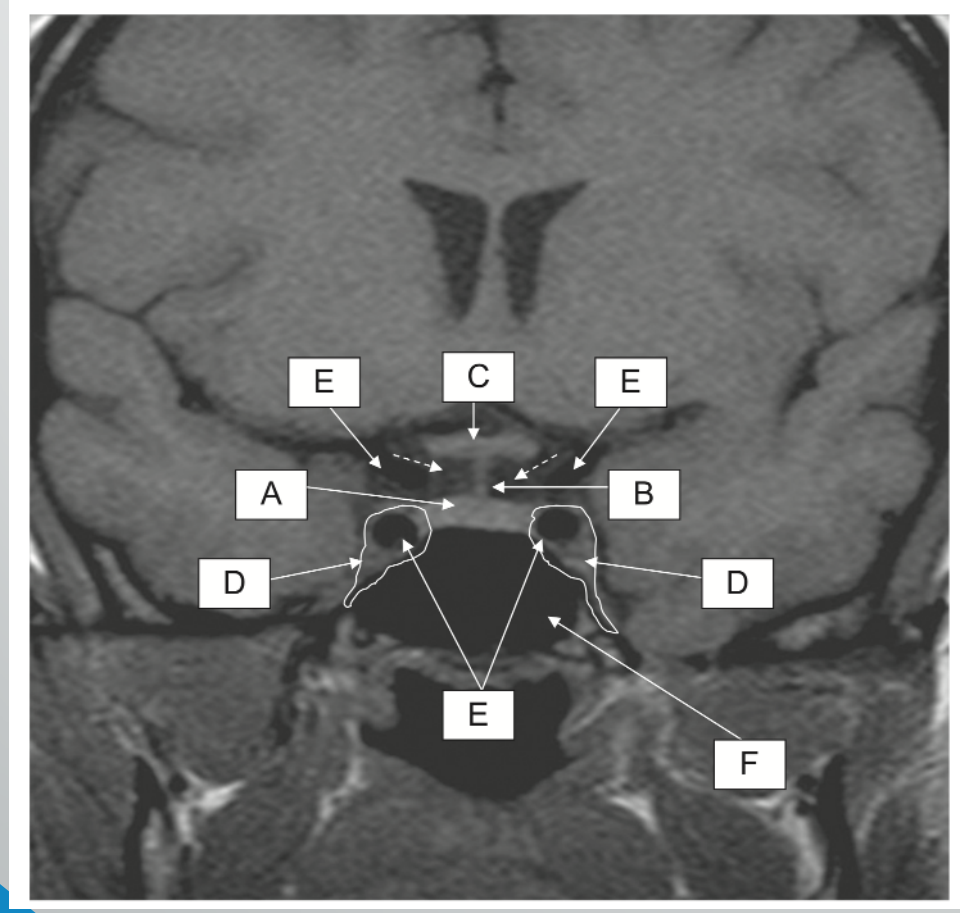

- T1-weighted coronal image without contrast: (A) pituitary gland, (B) pituitary stalk, (C) optic chiasm, (D) cavernous sinus, (E) internal carotid arteries, and (F) sphenoid sinus. The suprasellar cistern is commonly mentioned in radiology reports; it is the cerebrospinal fluid- filled space located above the sella turcica and under the hypothalamus. It contains the optic chiasm, the infundiblar stalk, and the circle of Willis (see white dashed arrows).

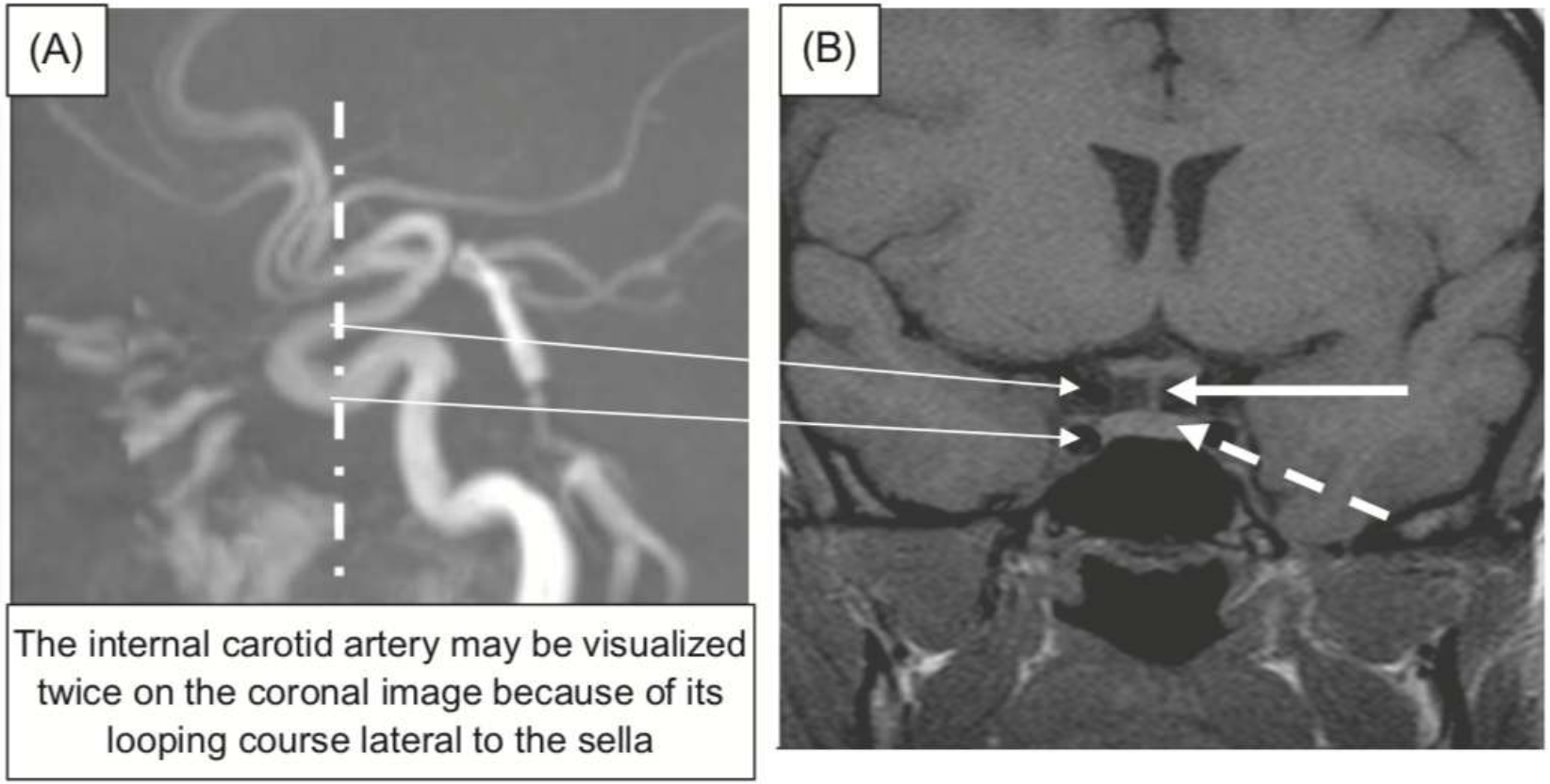

FIGURE 1.5 (A) Time-of-flight MRA, sagittal view of internal carotid arteries, and (B) coronal T1-weighted image without contrast.

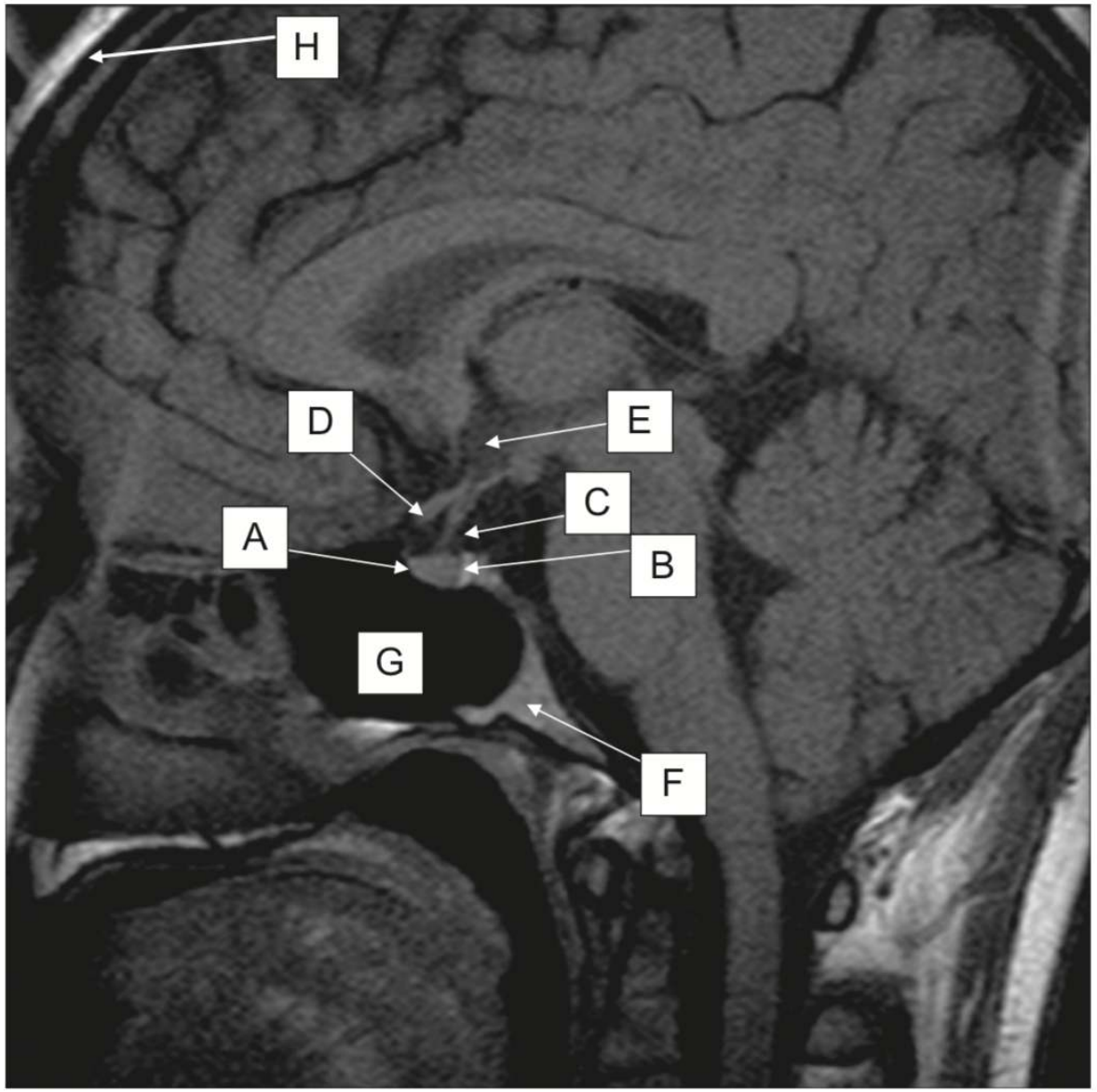

FIGURE 1.6 T1-weighted sagittal image without contrast: (A) anterior pituitary; (B) posterior pituitary; (C) pituitary stalk; (D) optic chiasm; (E) third ventricle, showing adjacent hypothalamus; (F) clivus; (G) sphenoid sinus; and (H) outer table of the calvarium.

PITUITARY ADENOMA

- A pituitary adenoma less than 1 cm is referred to as a microadenoma; otherwise, it is referred to as a macroadenoma.

PITUITARY MICROADENOMA

- Pituitary adenomas may appear isointense or hypointense on noncontrast T1-weighted imaging when compared to normal anterior pituitary tissue.
- Since most pituitary tumors are less vascular than normal pituitary tissue, they appear hypointense compared to the surrounding pituitary tissue during postcontrast studies
- The microadenoma on the T2-weighted image is not isointense compared to CSF (which appears bright), suggesting it is not cystic in nature

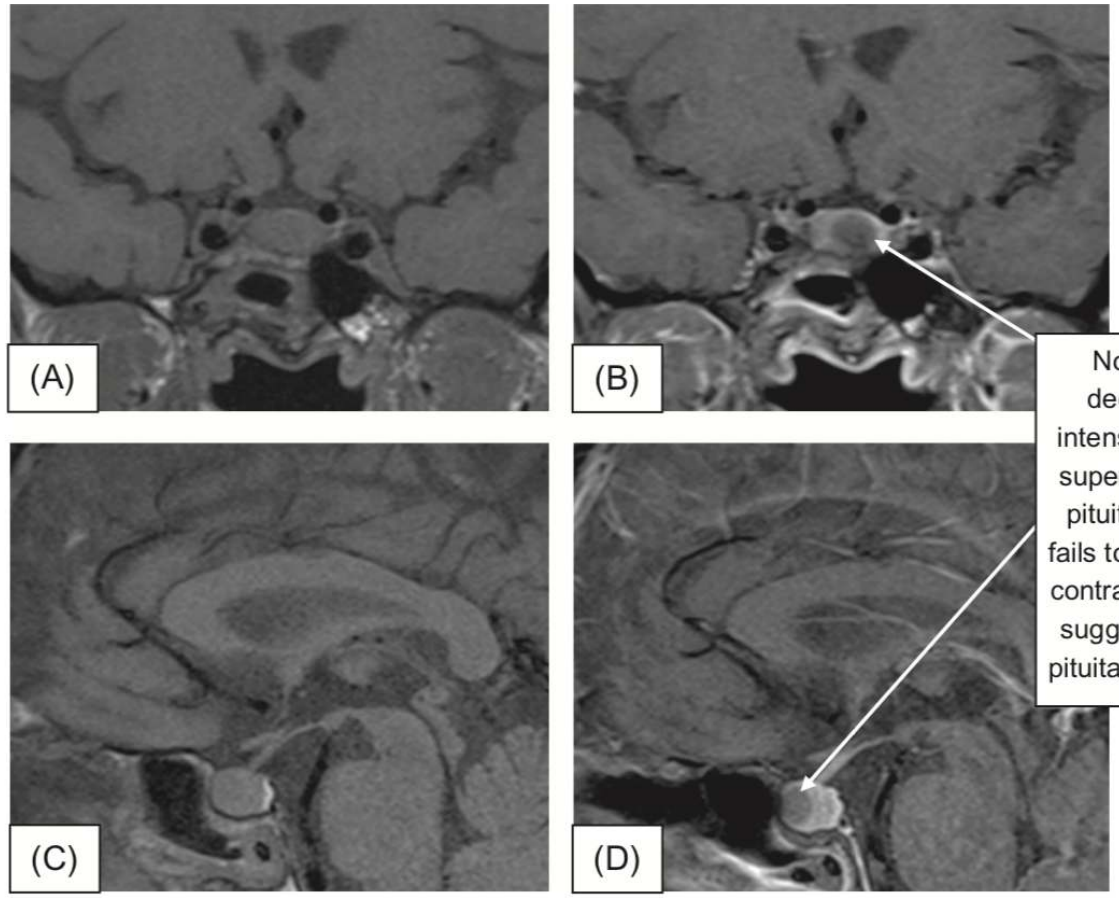

Note the area of decreased signal intensity in the lateral-superior aspect of the pituitary gland which fails to enhance post IV contrast. This finding is suggestive of a 4 mm pituitary microadenoma

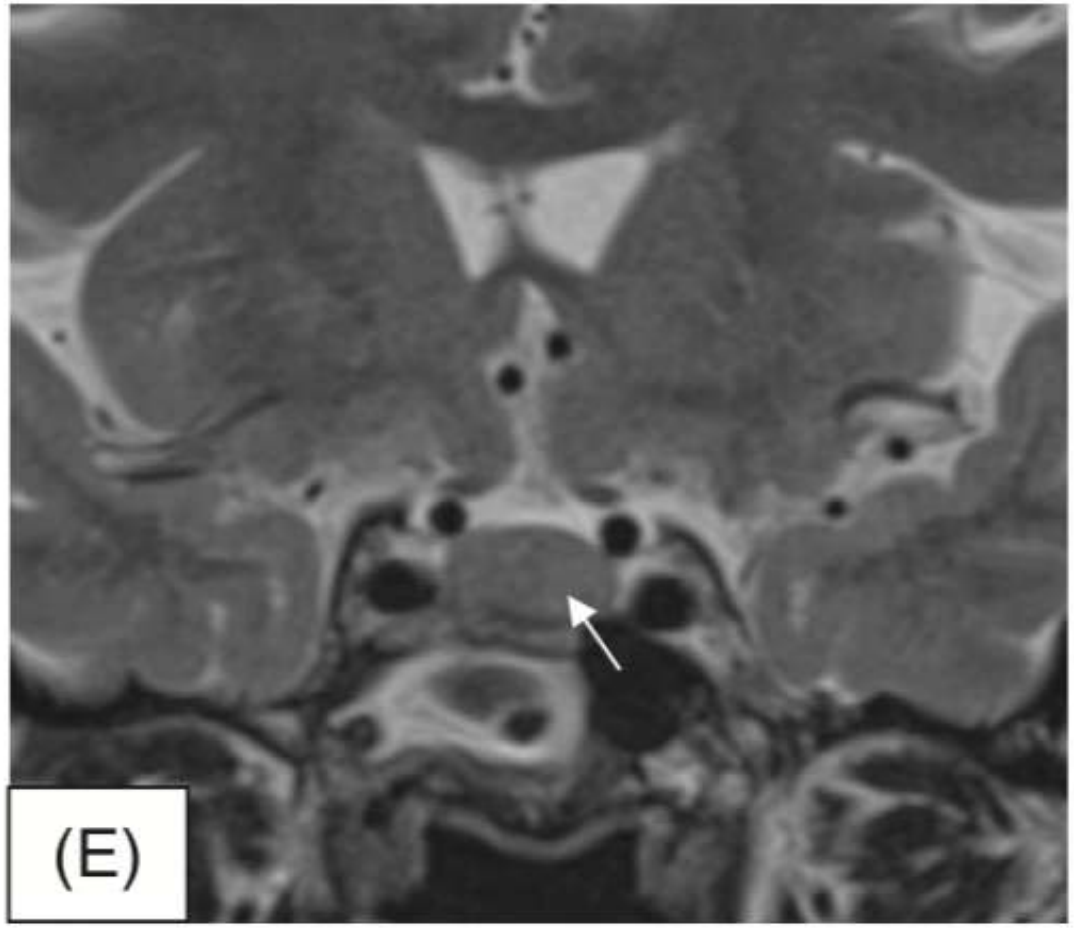

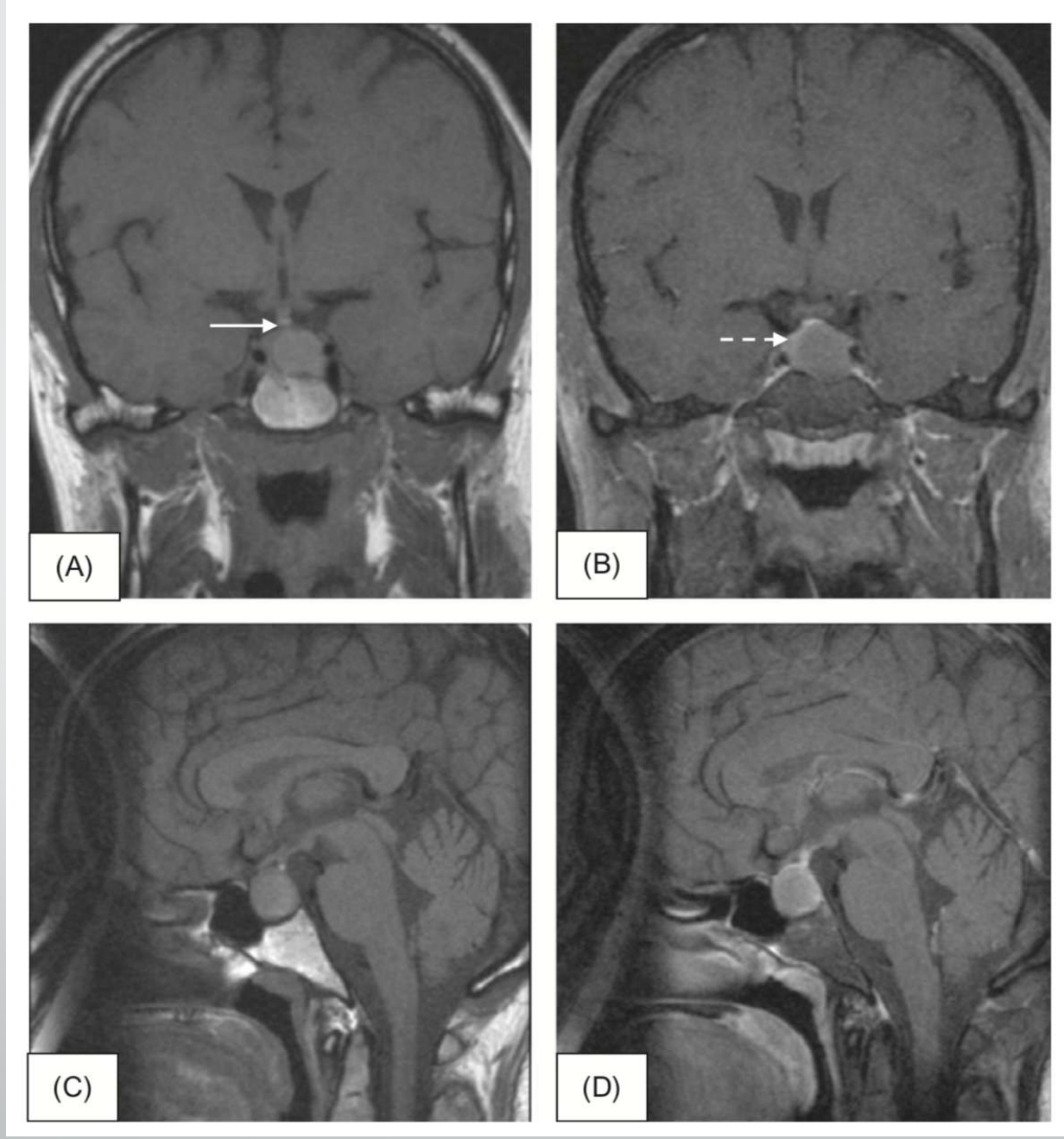
(A)
(B)
(C)
(D)

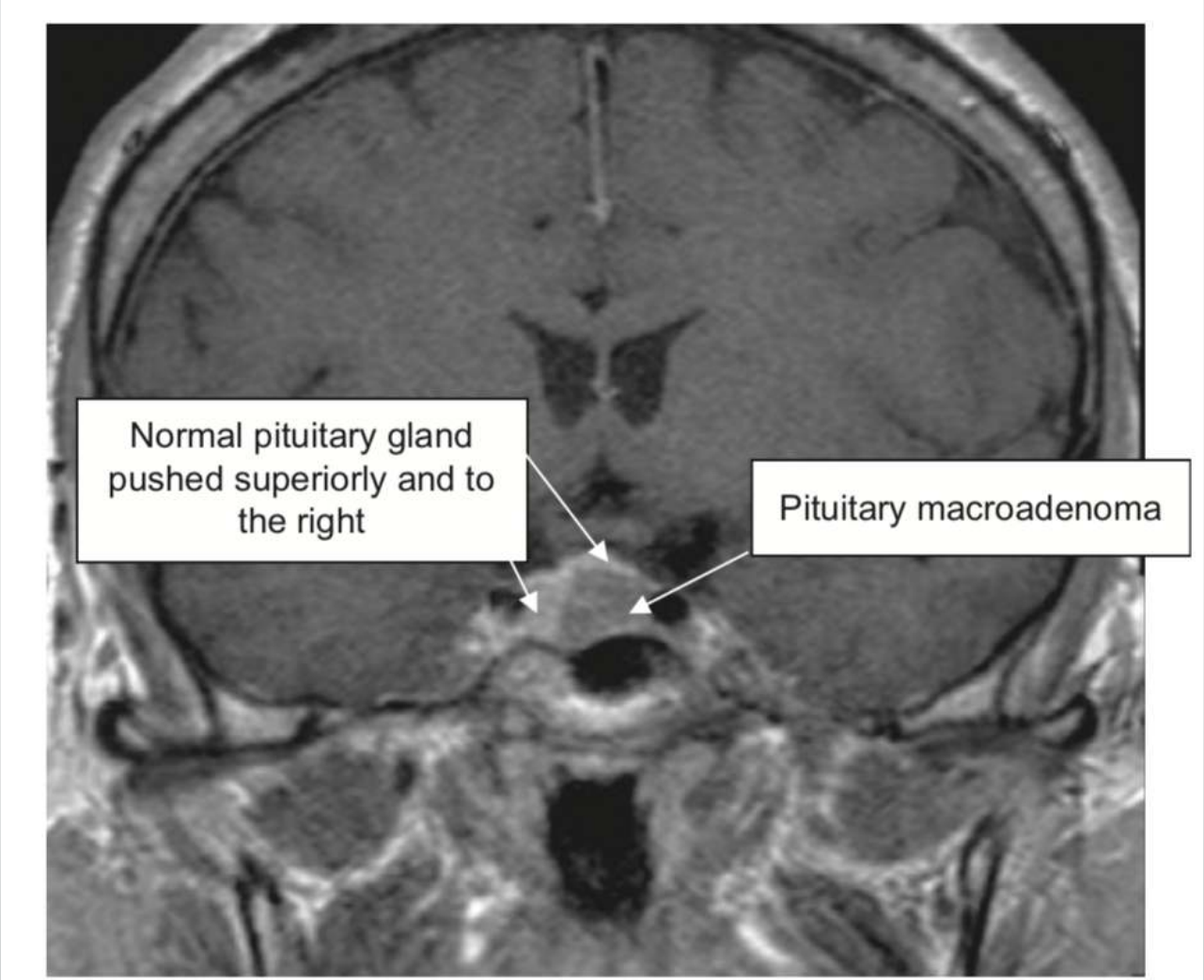

Pituitary macroadenoma: T1-weighted coronal image postcontrast.

PITUITARY MACROADENOMA WITH STALK DEVIATION

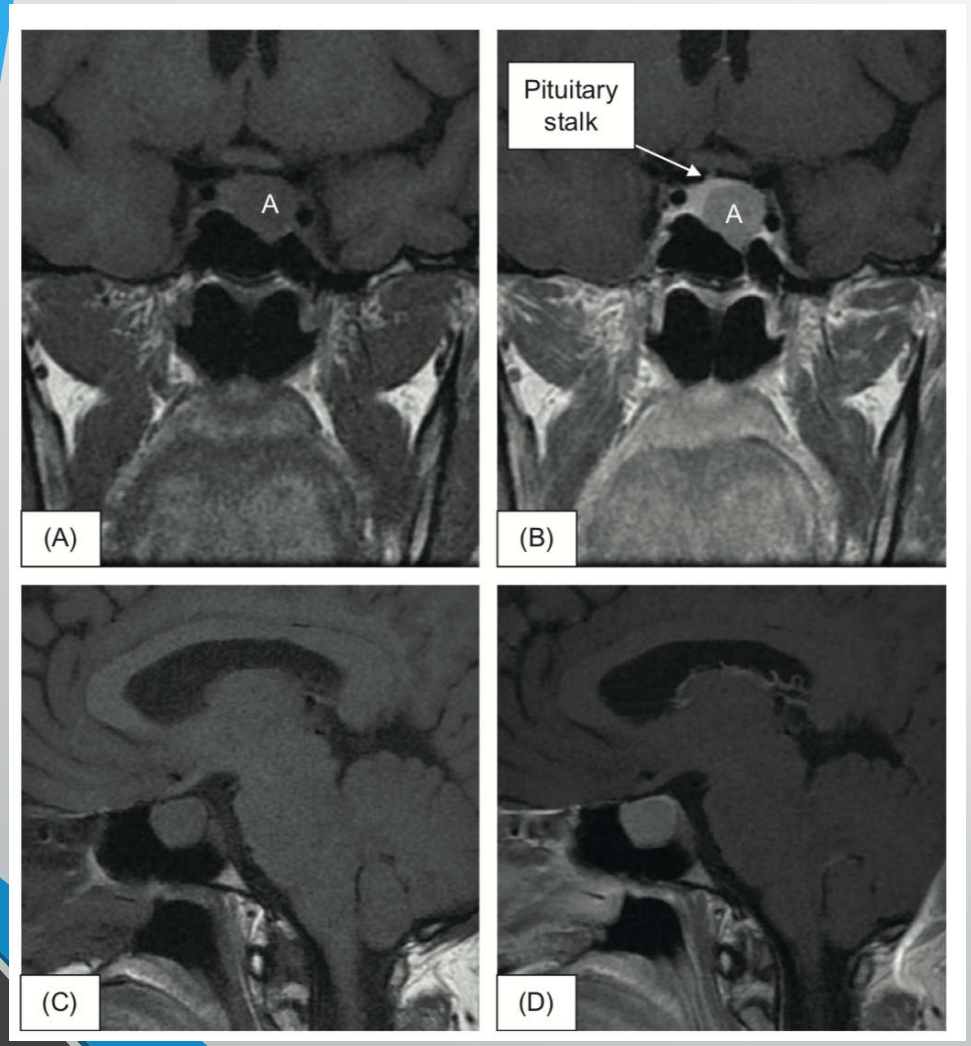

The sellar floor slopes downward to the left, and the mass does not abut or compress the optic chiasm.

PITUITARY MACROADENOMA WITH MILD SUPERIOR DISPLACEMENT ON THE OPTIC CHIASM

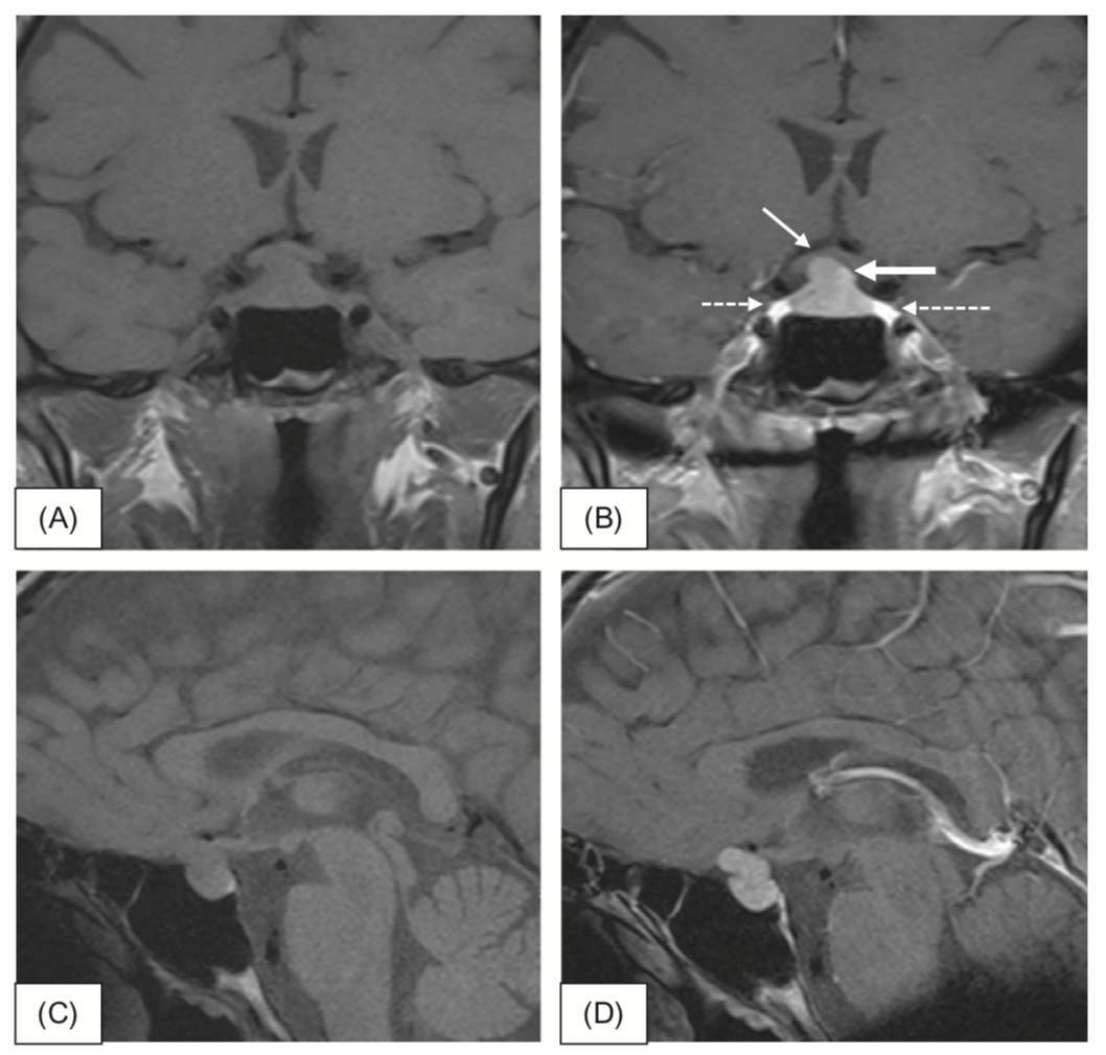

- Figure shows some subtle normal pituitary tissue seen as a slightly increased enhancement along the left lateral portion of the sellar mass (thick white arrow). Mild superior displacement of the optic chiasm is present (thin white arrow). The bright white areas seen bilateral to the inferior aspect of the mass are a normal enhancement of the cavernous sinuses (dashed white arrows).

LARGE INVASIVE PITUITARY MACROADENOMA

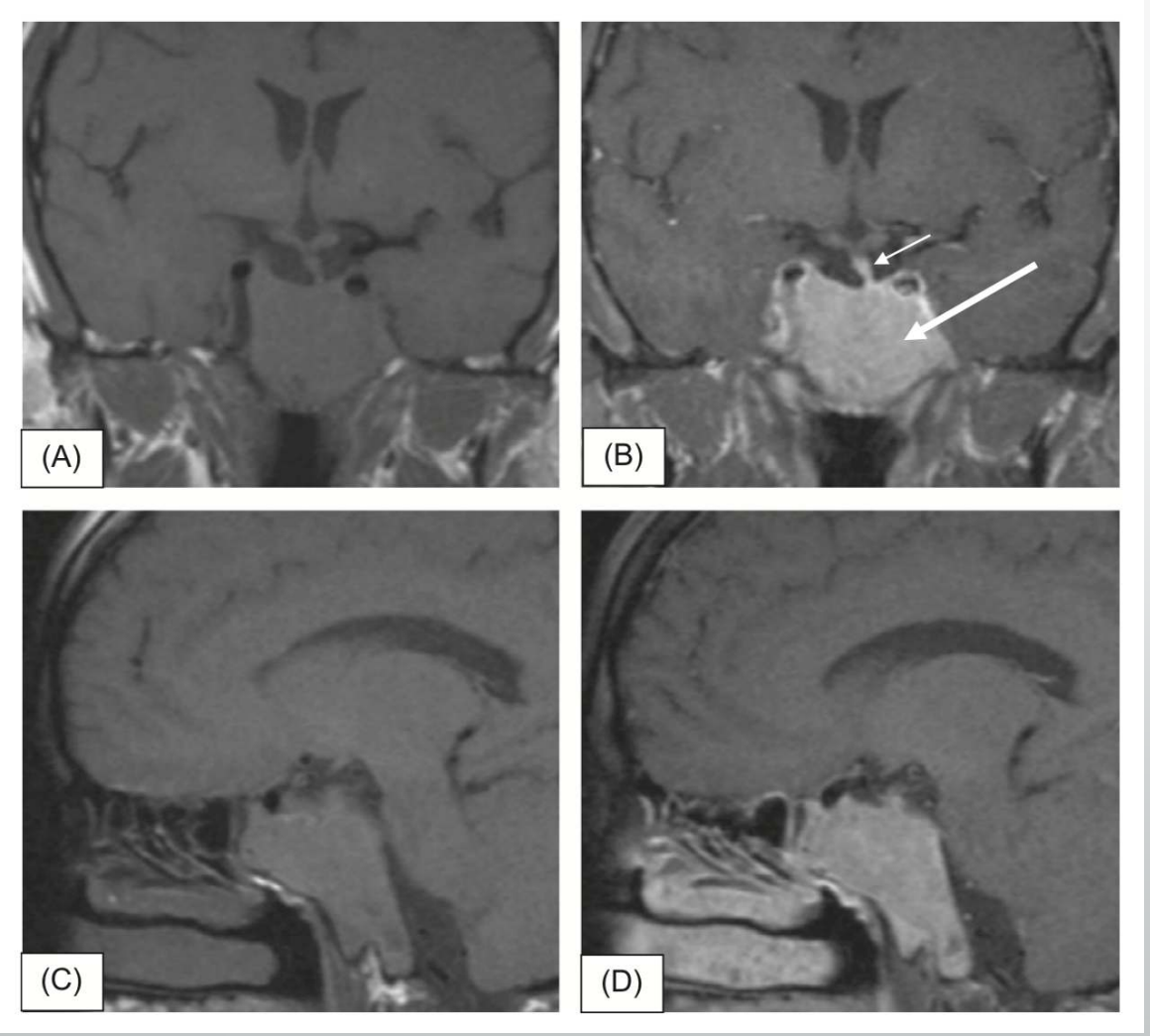

PATIENT WITH A GIANT INVASIVE PROLACTINOMA

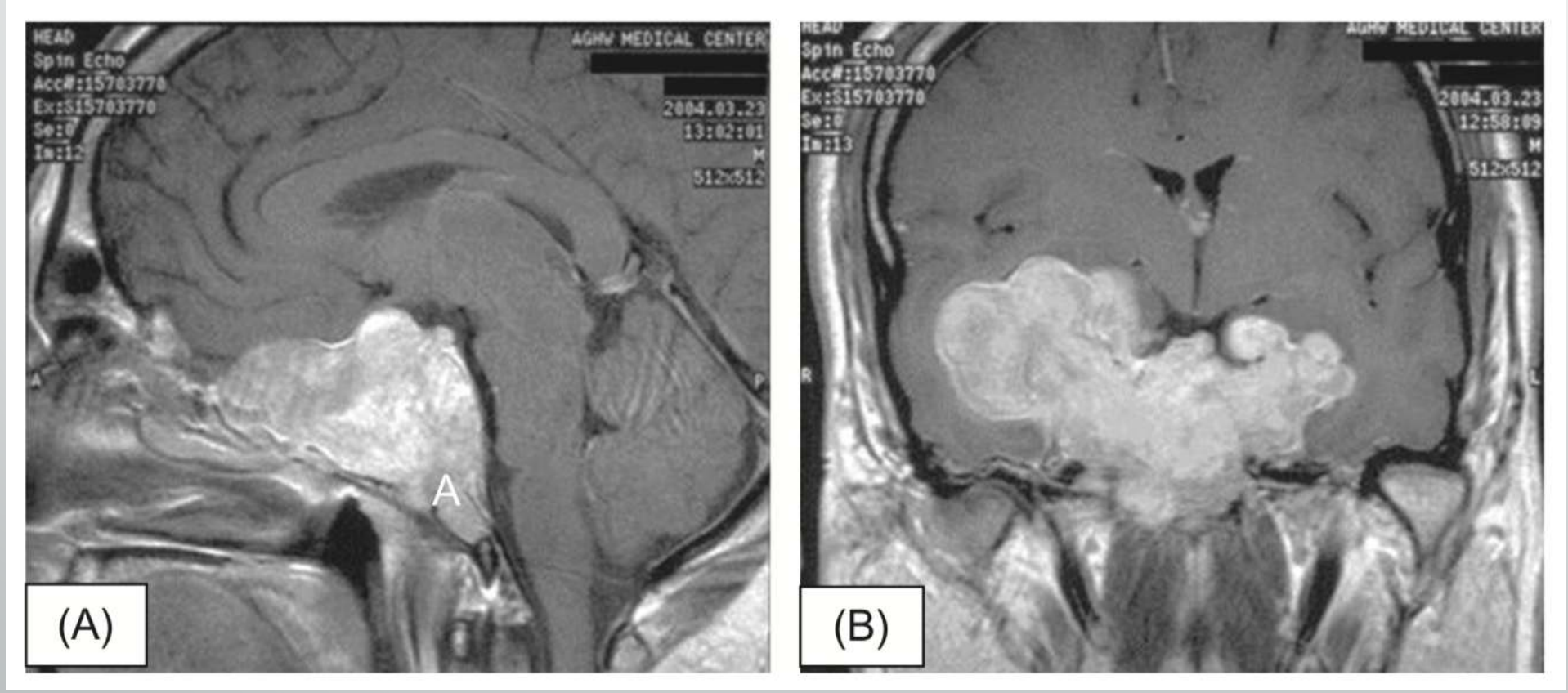

PITUITARY ADENOMA WITH CAVERNOUS SINUS INVASION

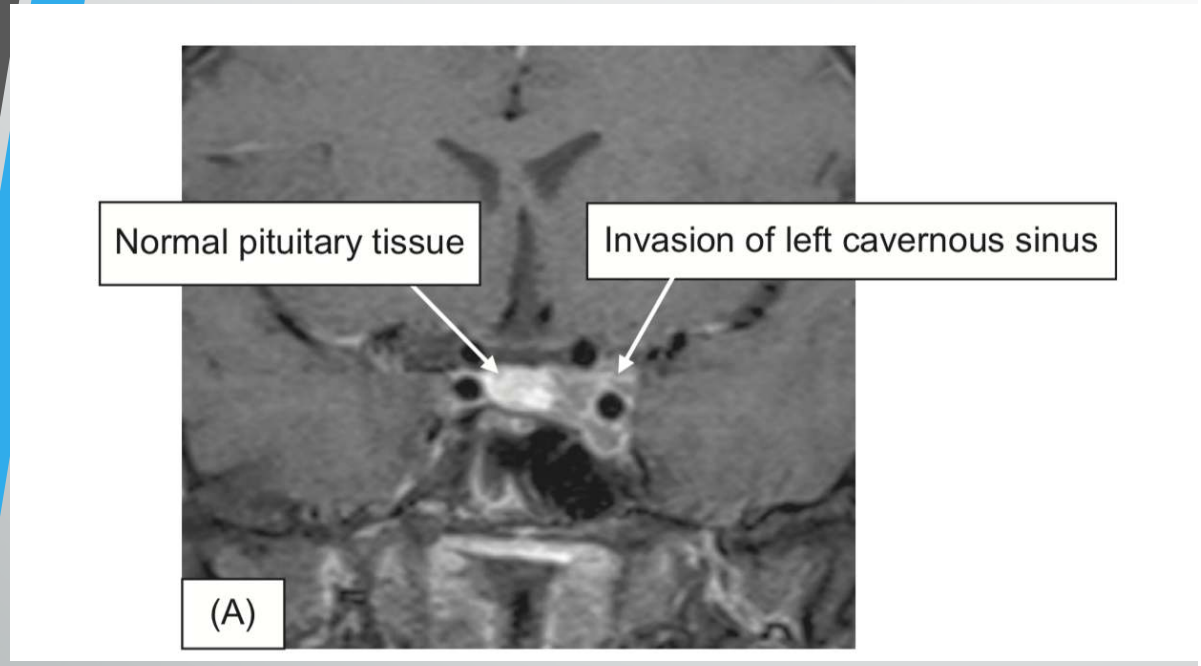

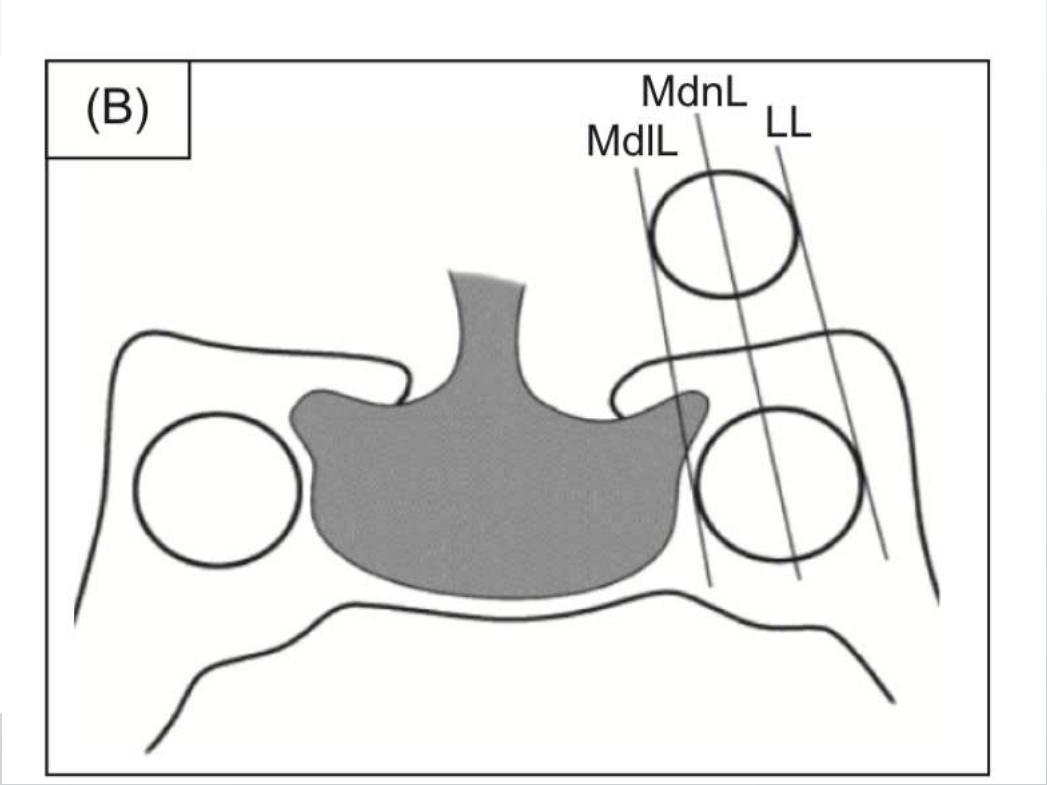

CYSTIC PITUITARY MACROADENOMA

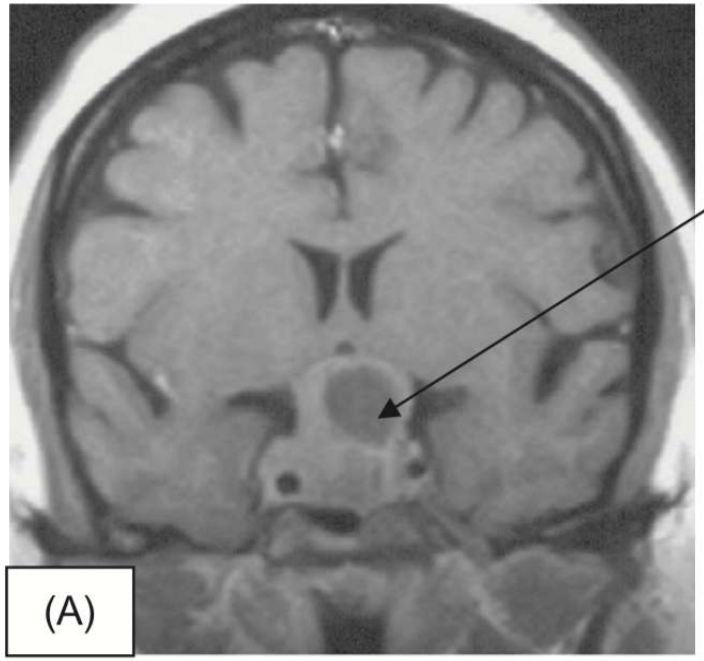

A pituitary macroadenoma containing a central area of signal hypointensity

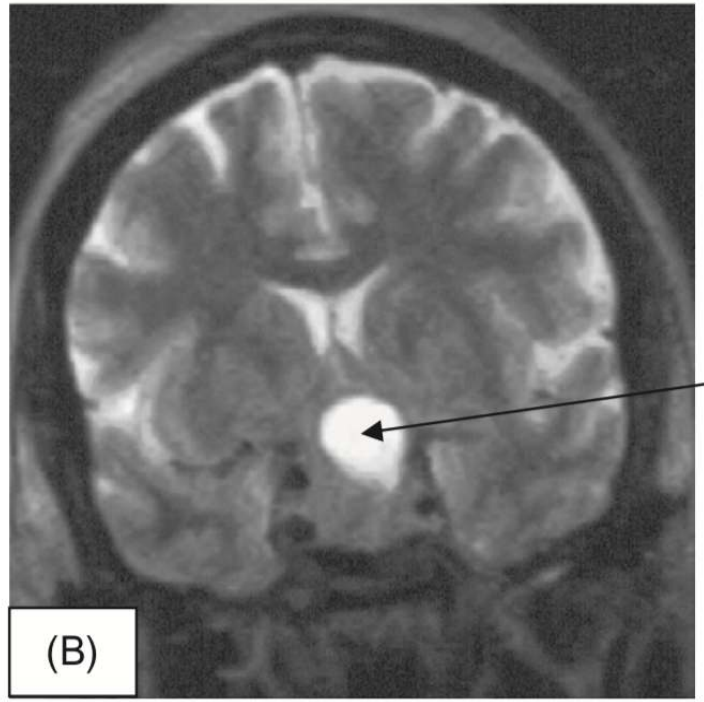

The area of T1 hypointensity (above) is now T2 isointense to CSF, a finding consistent with a cystic lesion

Atypical Adenoma

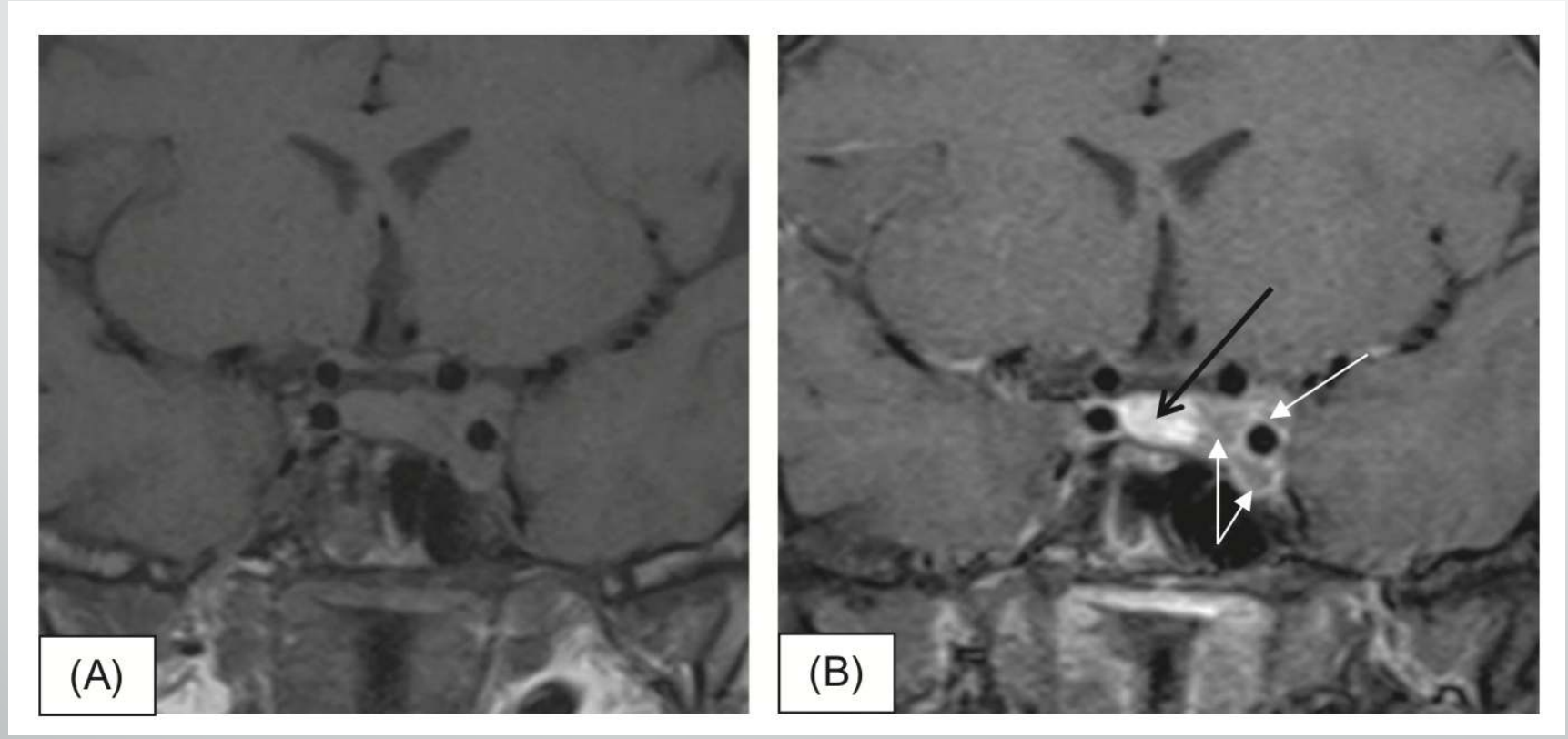

Ectopic Adenoma

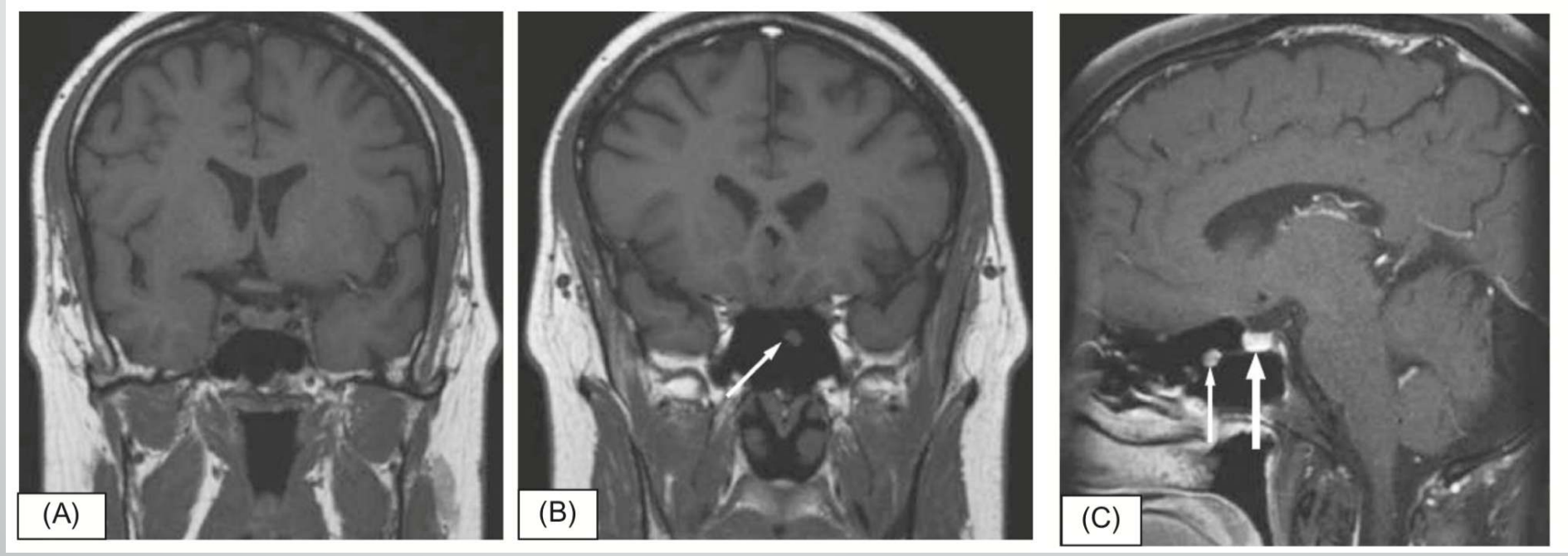

Bilateral inferior petrosal sinus sampling

Indications for BIPSS

- The indication for BIPSS differs among clinicians :

1- Some suggest that BIPSS should be reserved to patients with clinical and biochemical evidence of CD and negative or equivocal MRI findings

2-Others recommend BIPSS for patients with equivocal responses to hormone test or in cases of discrepancies between biochemistry and imaging findings

3-Others recommend BIPSS as a routine investigation in any patient with proven ACTH-dependent Cushing's syndrome

4-An additional reason to perform BIPSS is persistence of Cushing's syndrome after previous unsuccessful pituitary surgery, to ensure that the diagnosis of CD is correct.

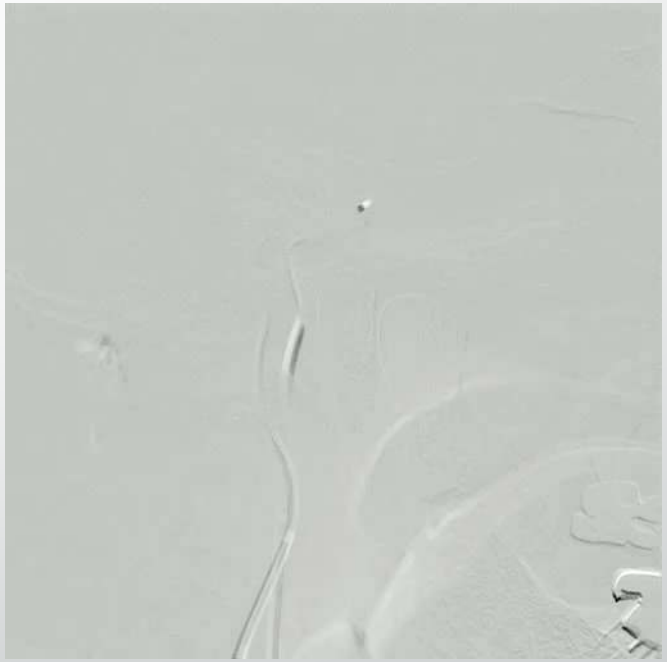

	-5 min	0	3 min	5 min	10 min
ACTH(pg/ml)IPS R	739	>1250	>1250	>1250	>1250
ACTH(Pg/ml)IPS L	333	208	655	378	609
ACTH(pg/ml) femoral	129	107	96.2	95	97.8
Prolactin(ng/ml) R		27.8			
Prolactin(ng/ml)L		14.8			
Prolactin(ng/ml)F		9.77			

PITUITARY HYPERPLASIA

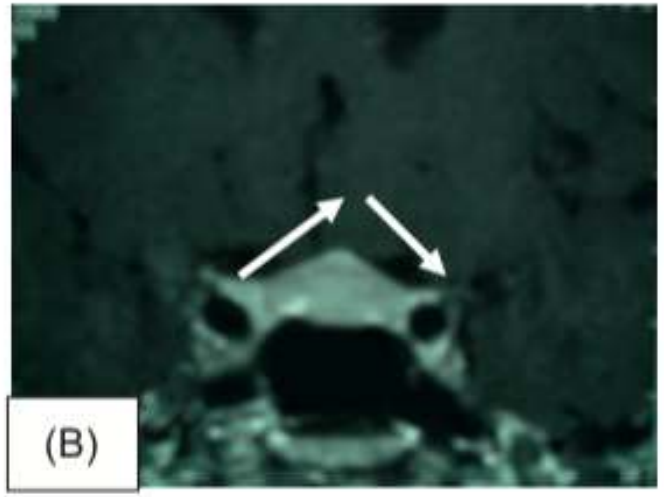

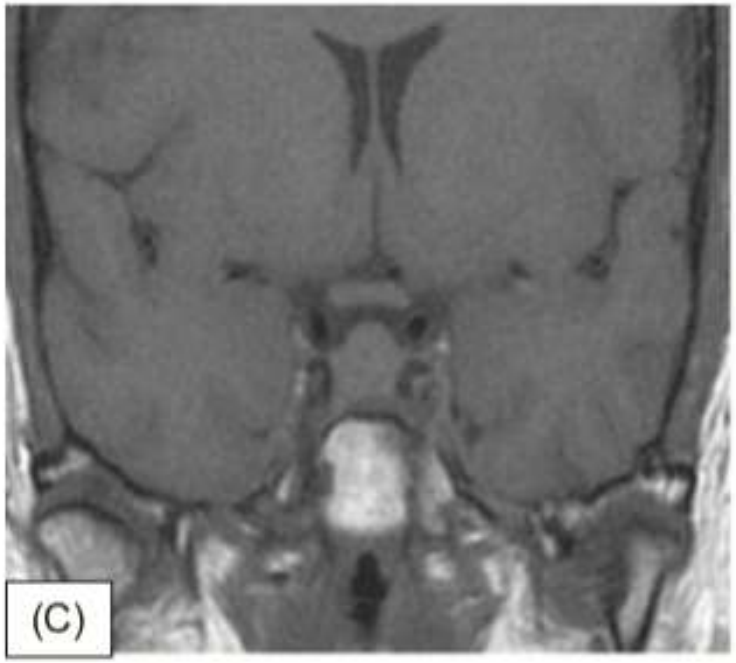

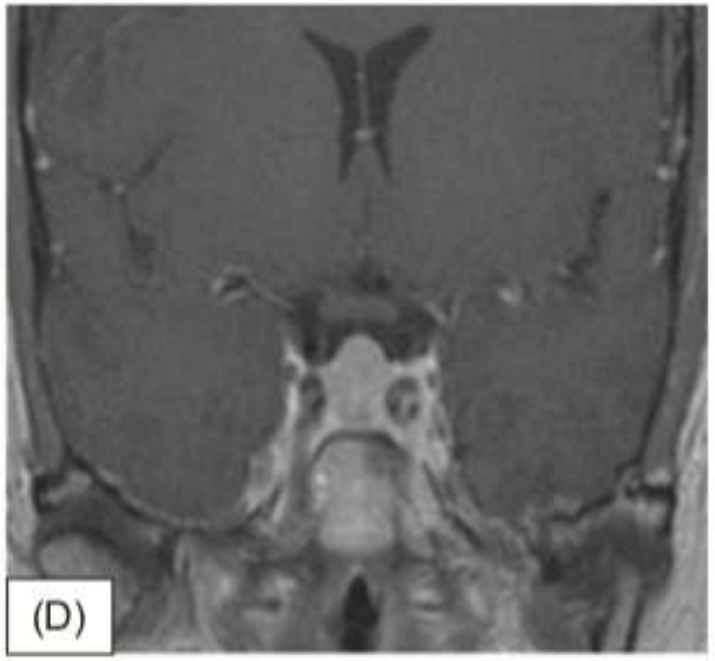

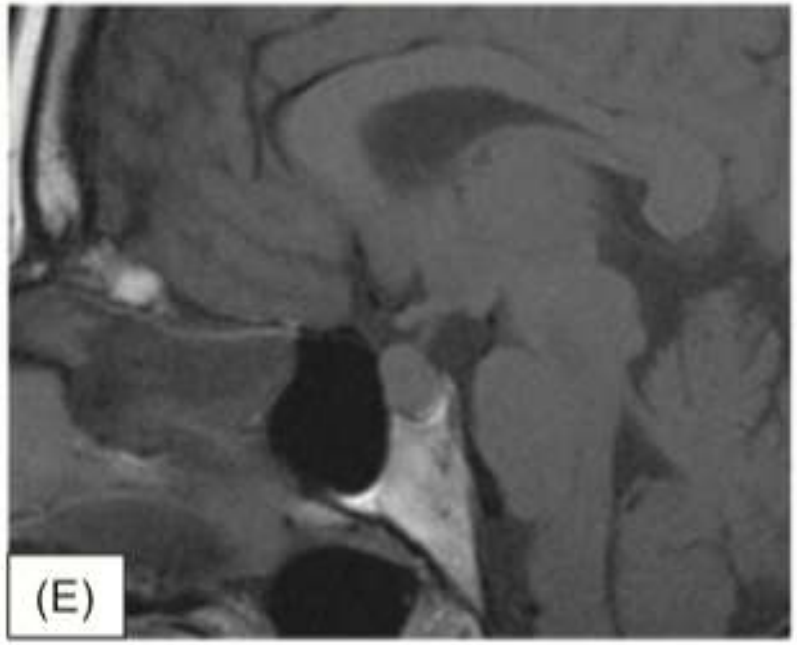

VASCULAR LESIONS (ANEURYSM)

- Identifying vascular lesions involving the sella is important.
- Additional imaging studies (MR angiogram, CT angiogram, etc.) are often required to further evaluate lesions that have MRI characteristics suggesting the possibility of a vascular lesion.
- Imaging features that are suggestive of a vascular etiology are artifacts due to flowing blood or a blood clot. When flowing protons have a speed above a certain threshold (which depends on the sequence), they no longer contribute any MRI signal and appear black on an image, often termed a “flow void.” This feature is particularly apparent on a T2-weighted sequence, and less so on a noncontrast T1-weighted sequence.
- After the administration of contrast there is often avid enhancement, but the pattern of enhancement may have a smooth gradation of intensity across the lesion (sometimes termed “shading”), whose pattern does not conform to any expected underlying anatomy.
- Finally, the presence of clot will create a heterogeneous signal adjacent to flow voids, which does not enhance.

Sometimes the clot will have a web- like or crecentic morphology

VASCULAR LESIONS (ANEURYSM)

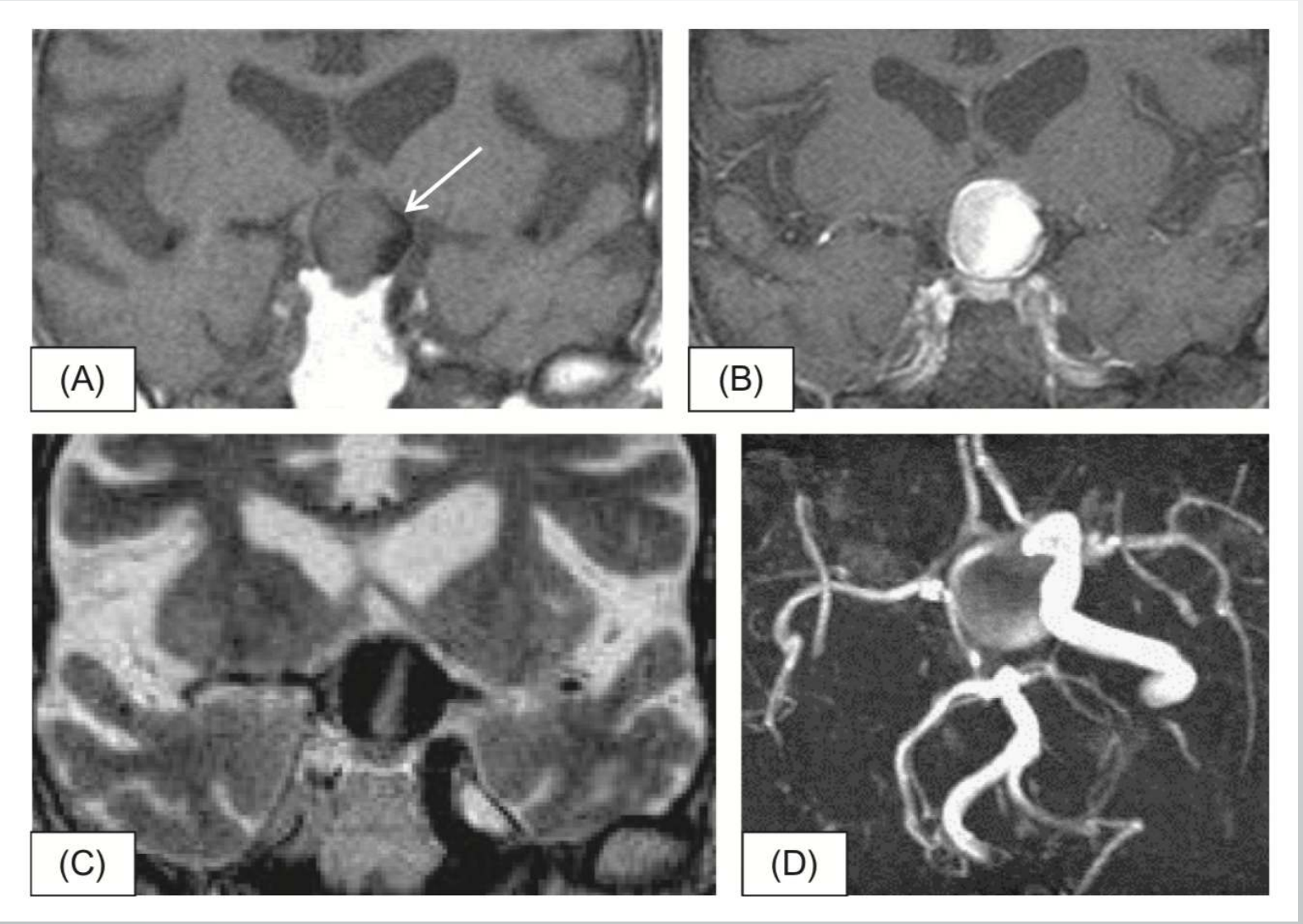

POSTOPERATIVE PITUITARY IMAGING

- Post-surgical evaluation of the pituitary gland in MRI is difficult because of a change in anatomical conditions.
- It depends also on numerous other factors, including: size and expansion of the tumour before surgery, type of surgical access, quality and volume of implanted materials and time of its resorption.

Characteristics of the implanted materials on MRI

- The knowledge of MRI characteristics of the materials implanted at the sellar region is very important in postoperative diagnosis of pituitary tumours
- Filling materials are foreign or autogenic bodies that do not become vascularised
- The implanted materials:

1-fat

2-muscle with fascia

3-implanted titanium

4-Haemostatic materials (oxidised cellulose (Oxycel or Surgicel), spongostan (Gelfoam), tissue glue (Tissucol or Beriplast), bone wax (to restrain bleeding from bone)

The implanted materials

- Liquorrhoea requires a reconstructive operation of sella, with the use autogenic fascia, lyophilisated dura mater or tissue glue.
- Next, the sella is sealed with a muscle or flakes of oxidised cellulose.
- To close the bottom of the sella, it is necessary to use a fragment of the collected cartilaginous septum from nose, the vomer, or a silicon plate.
- To protect the postresection site and to reinforce the bottom of the sella, an autogenic fat graft is implanted in the sphenoidal sinus. The graft is collected from the fatty tissue of the lateral part of the thigh or from the patient's abdomen

Fatty filling material

- Fatty filling material was represented :
- by a characteristic signal of high intensity in T1-weighted images.
- It was located in the lumen of the sphenoidal sinus, or its fragments were present intrasellarly.
- In the majority of patients, the fragments of fatty tissue were observed for a long time for up to 112 months (over 9 years) after the procedure

Muscle with fascia

- Muscle with fascia presented :
- in T1-weighted images as a round hypointense structure, located in the lumen of the sphenoidal sinus.
- After contrast medium administration, the peripheral part of that material got slightly enhanced.
- In T2-weighted images, the implanted muscle with fascia produced a high signal intensity (increased signal intensity corresponded to degenerative processes of the denervated muscle).
- Fascia presented as a line of low signal intensity.
- follow-up time, no decrease in the volume of the implanted muscle and fascia was found, as it was seen in case of fat which was being progressively absorbed.

The implanted titanium mesh

- The implanted titanium mesh was identified:
- as a line of an absent signal intensity within the bottom of the sella, which corresponded to the presence of a metal foreign body.

Haemostatic material

- Haemostatic material (according to neurosurgical reports – Oxycel) showed a low signal intensity surrounded by a line of a delicate enhancement after contrast administration.
- spongostan and Surgicel (Oxycel) may be recognised only on an early performed MRI, i.e. within 24–48 hours after the procedure, because afterwards, the materials begin to undergo a progressive degeneration and their radiological identification becomes harder
- these materials are normally recognisable on MRI for up to 3–6 months after the procedure
- After contrast administration, the central part of the haemostatic material remained hypointense, with peripheral rim of enhancement. This peripheral enhancement is caused by granulation tissue forming around the implanted material.
- It should be underscored that a hypointense mass with peripheral enhancement after contrast administration is not characteristic for the filling material only. It may also correspond to the presence of a fluid cistern, regions of necrosis within the tumour or cicatrical fibrous tissue with granulation around it

CASE 1

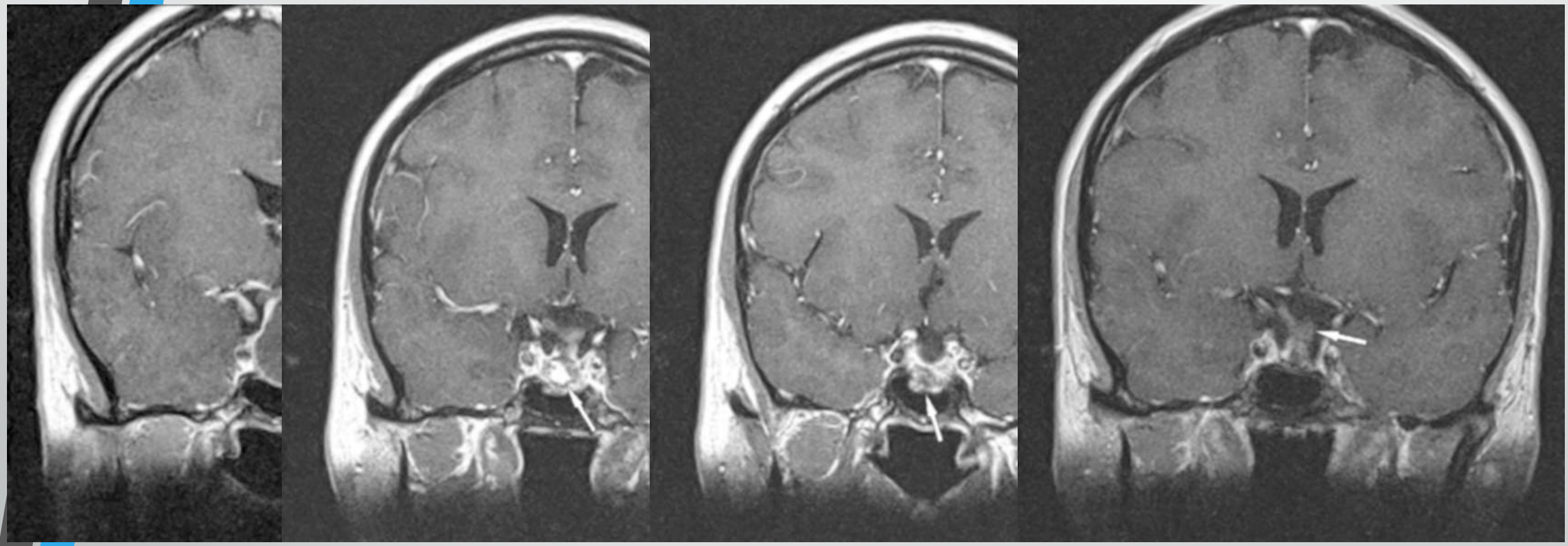

A 27-year-old woman admitted to the Department of Endocrinology due to hyperprolactinaemia of 311 ng/ml (N=1.9–25.0 ng/ml), diagnosed under outpatient conditions. Moreover, the patient reported secondary amenorrhea for approx. 3 years. The performed MRI showed a large endo- and suprasellar tumour of solid-cystic type, measuring 2.8×1.9 cm

CASE2

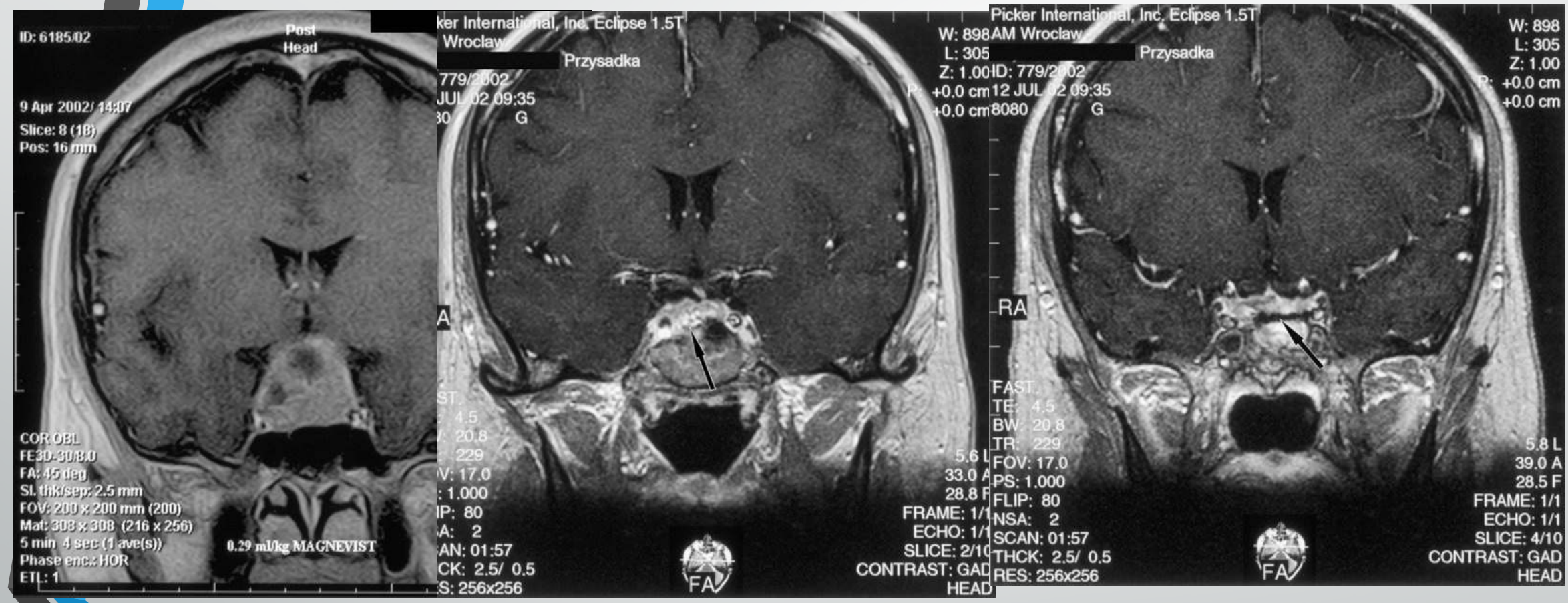

A 38-year old women admitted to the Department of Neurosurgery for the operation of prolactin secreting macroadenoma (macroprolactinoma). The patient reported headaches present for about 6 last years, menstruation abnormalities with galactorrhoea for the last two years and vision problems experienced for about half a year. The MRI examination showed a solid-cystic tumour of the pituitary gland,

CASE3

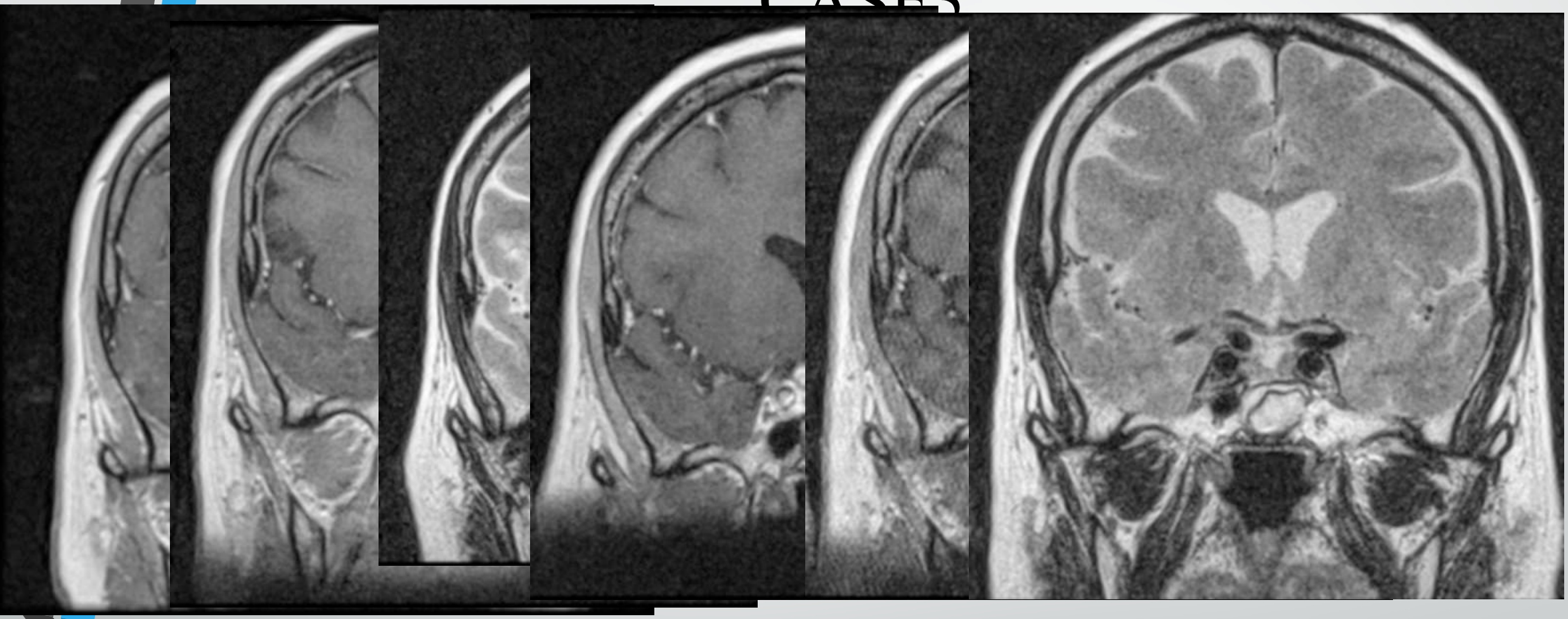

A 70-year-old woman, admitted to the Department of Endocrinology due to typical clinical features of acromegaly becoming more pronounced in the last 10 years: enlarging hands, feet, and tongue, accompanied by headaches. The performed MRI revealed a hypointense area of 8 mm in diameter, highlighting the outlines of the pituitary gland and located within the anterior pituitary lobe, on the right. This image corresponded to the presence of microadenoma

Conclusions

- The knowledge of MRI characteristics of the filling materials implanted during the transspenoidal procedure is a very important factor which may help in the differential diagnosis of intra- and perisellar structures in patients after pituitary tumour surgery.
- Haemostatic materials can be seen on MRI for only a short period of time after the procedure (1 month). Others, such as fat, may be present for as long as even 10 years after the procedure.
- T2-weighted images are very useful in the postoperative evaluation of the implanted muscle with fascia, for a long time after the resection.

Visible Fat Pad

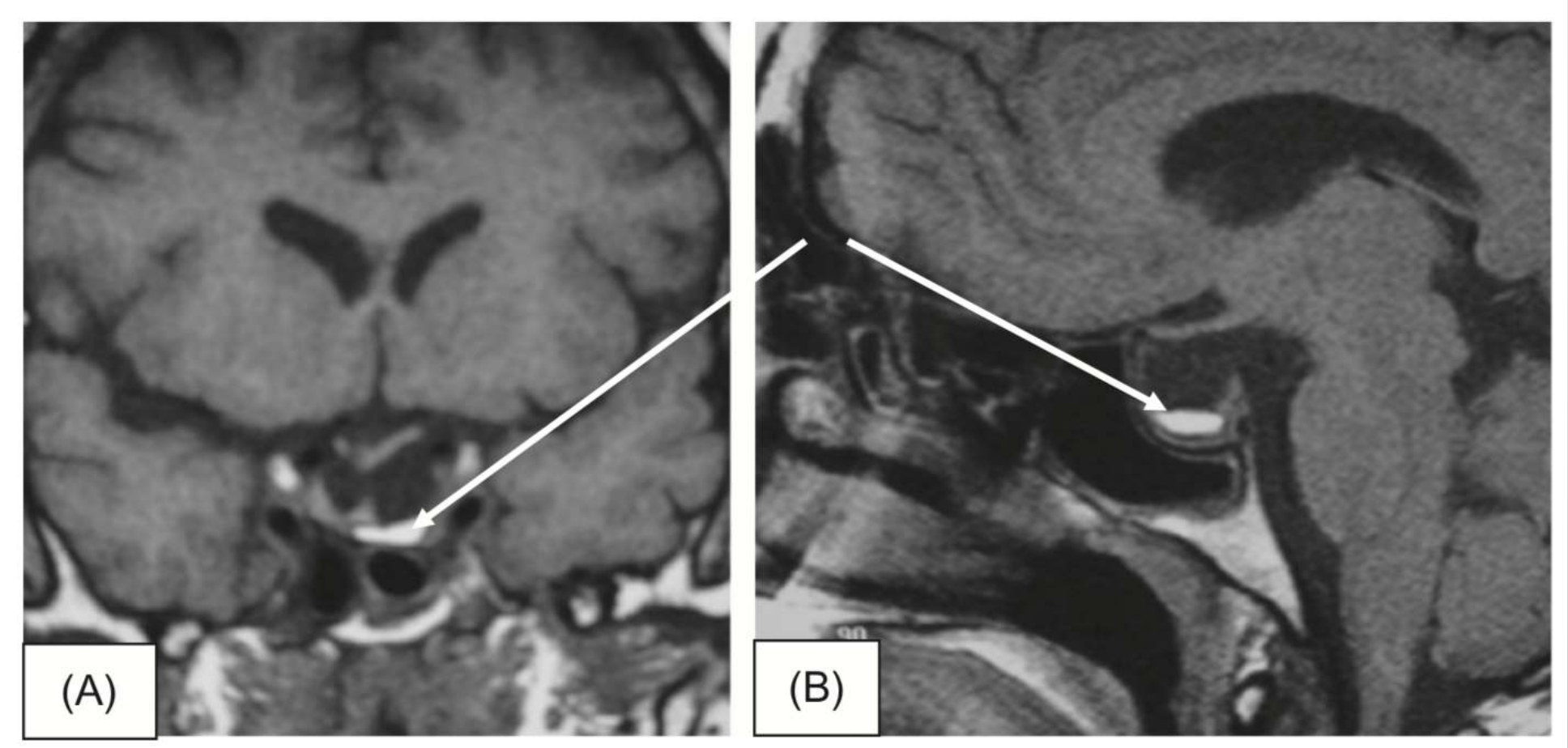

Sellar Remodeling Post-Pituitary Surgery

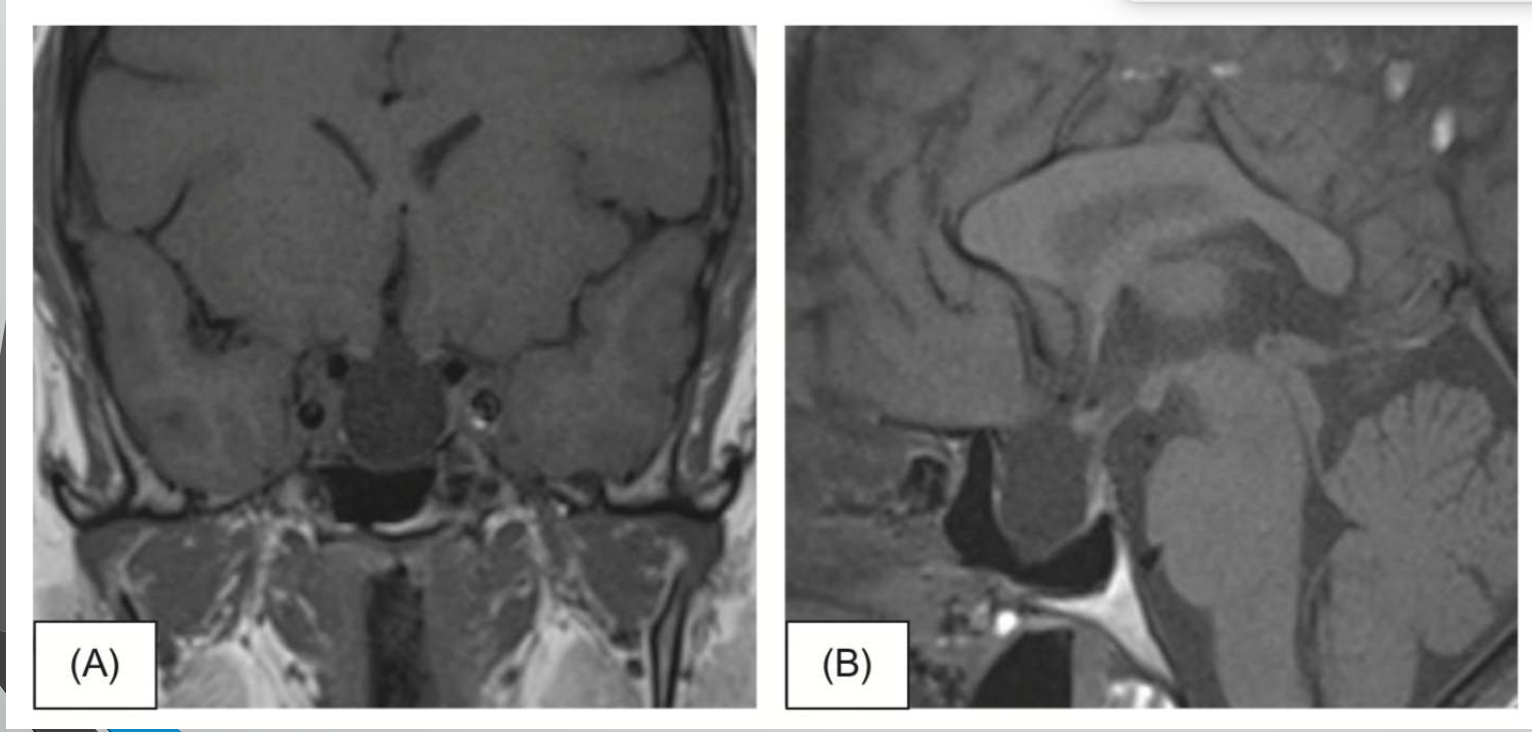

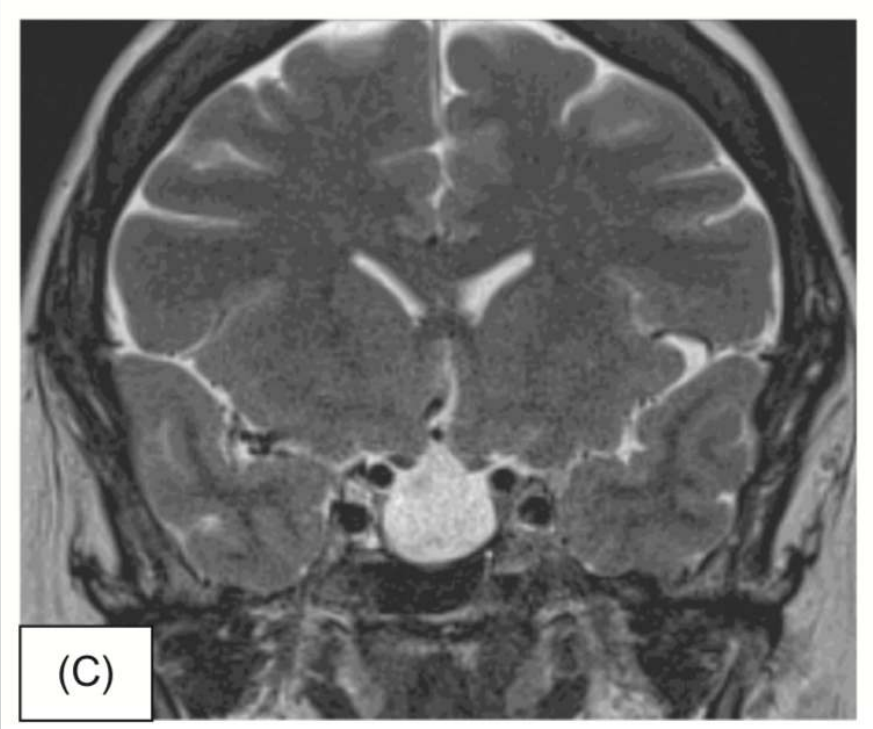

Immediate MR scan following surgery confirmed residual tumor in a 27-year-old woman with growth hormone-secreting tumor.

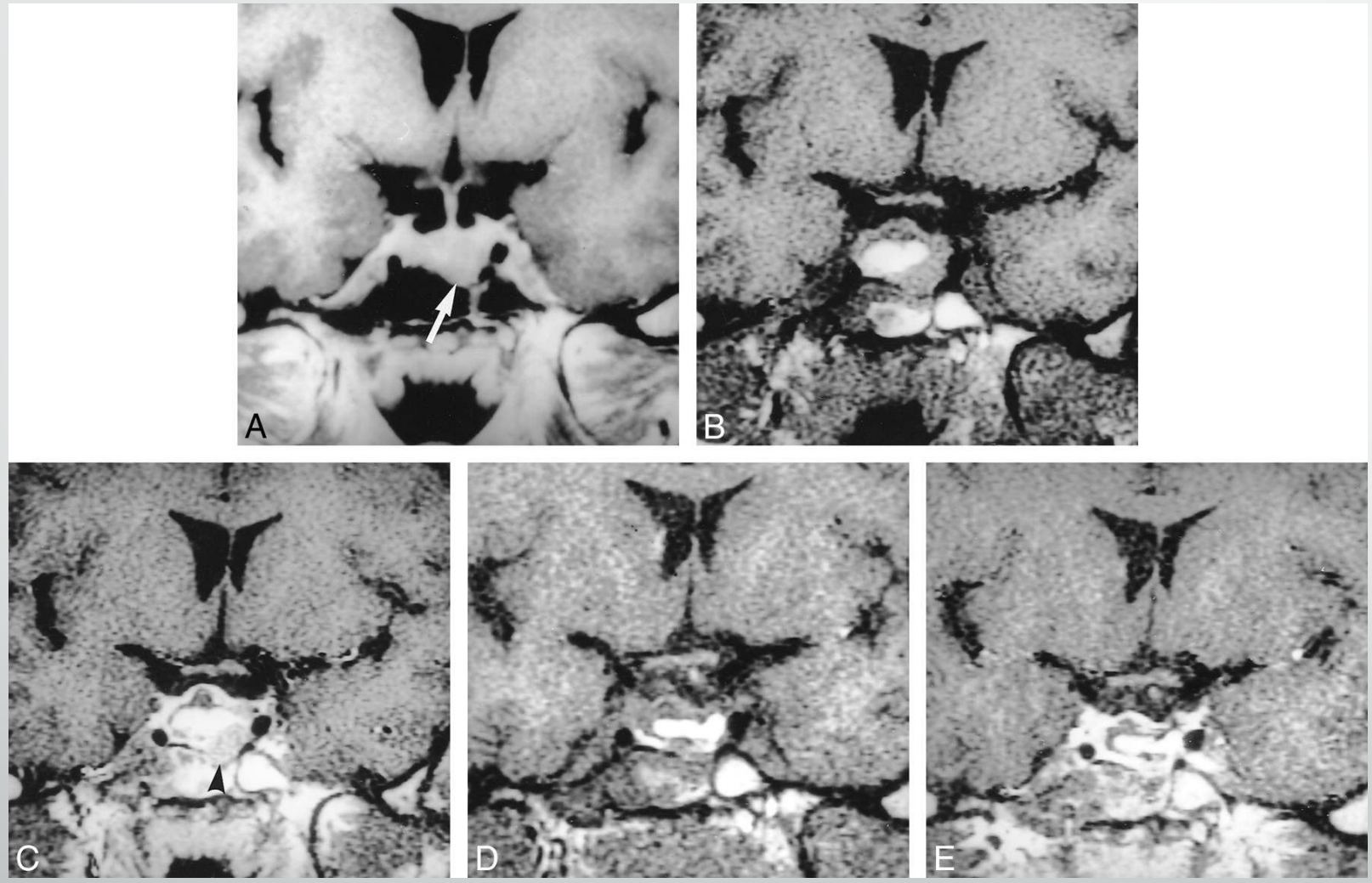

Pyeong-Ho Yoon et al. AJNR Am J Neuroradiol 2001;22:1097-1104

AJNR
AMERICAN JOURNAL OF NEURORADIOLOGY

Differentiation of postoperative changes and residual tumors in dynamic contrast-enhanced sella MRI after transsphenoidal resection of pituitary adenoma

Kim, Ha Youn MD[a]; Kim, Sung Tae MD[b,*]; Kim, Hyung-Jin MD[b]; Jeon, Pyoung MD[b]; Byun, Hong Sik MD[b]; Kim, Yi Kyung MD[b]; Cha, Jihoon MD[c]; Park, Gyeong Min MD[d]; Nam, Do-Hyun MD[e]; Kong, Doo-Sik MD[e]

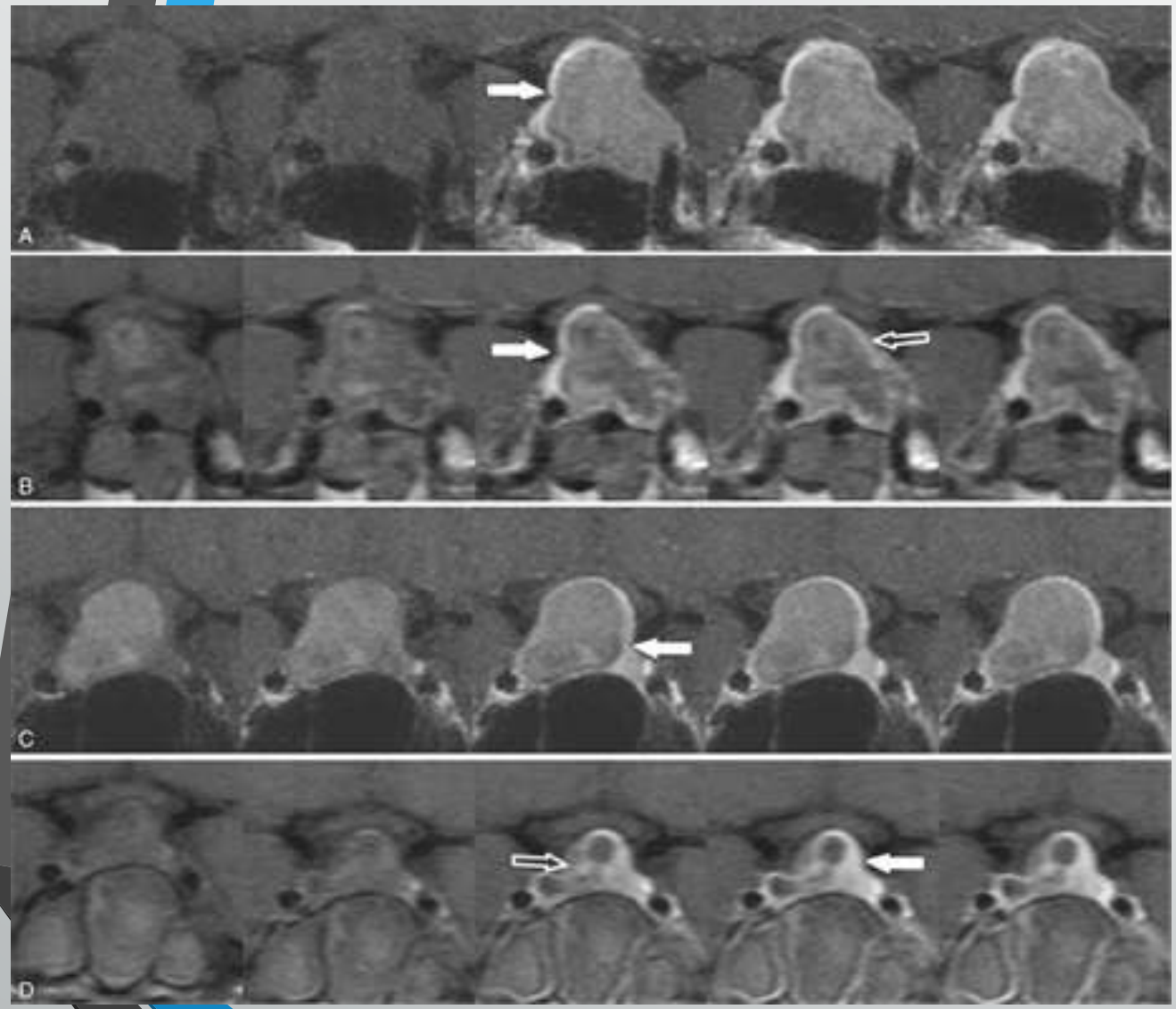

- Normal gland on preoperative and postoperative dynamic contrast-enhanced MR images of 2 residual enhancement patterns. Peripheral enhancement pattern (a, b) and nodular enhancement pattern (c, d). On preoperative MRI (a, c), the location of the normal gland (solid arrows) was demonstrated against the pituitary adenoma. Upon immediate postoperative MRI (b, d), the normal gland (solid arrows) and residual enhancing lesion (open arrows) were delineated.MRI = magnetic resonance imaging.

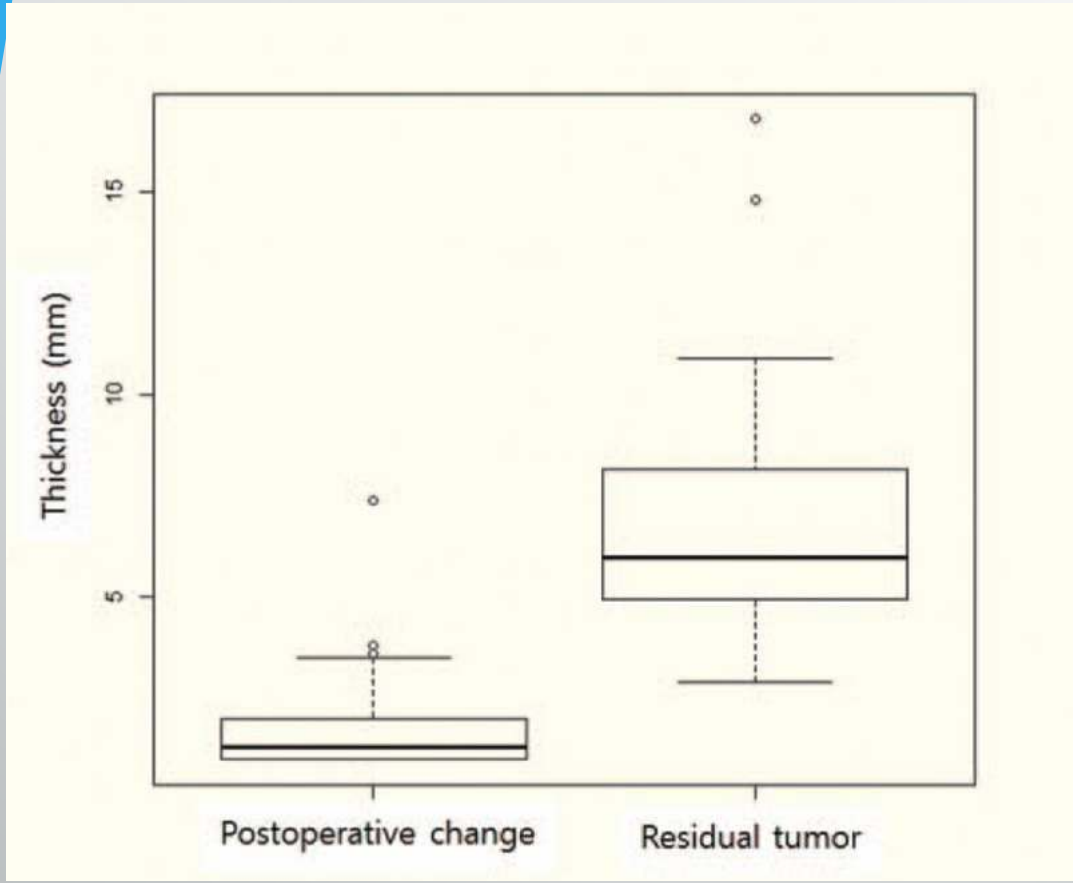

- Thickness of residual enhancing lesions. The distributions of residual enhancing lesion thickness in the 2 groups. Thickness of postoperative changes and residual tumors were significantly different ($P < .05$). Horizontal line, median; ends of the boxes, upper and lower quartiles; vertical lines, full range of values.

Enhancement pattern	Patients with residual tumor	Patients with postoperative change	Total
Peripheral	3 (4.6 mm, 2.9–6.2)	30 (1.6 mm, 1.0–3.8)	33 (1.8 mm, 1.0–6.2)
Nodular	16 (7.5 mm, 4.0–16.8)	3 (4.7 mm, 3.1–7.4)	19 (7.1 mm, 3.1–16.8)
Total	19 (7.1 mm, 2.9–16.8)	33 (1.9 mm, 1.0–7.4)	

Parentheses are the mean thickness and range with millimeter measure.

- Enhancement pattern and thickness of early postoperative pituitary mass.

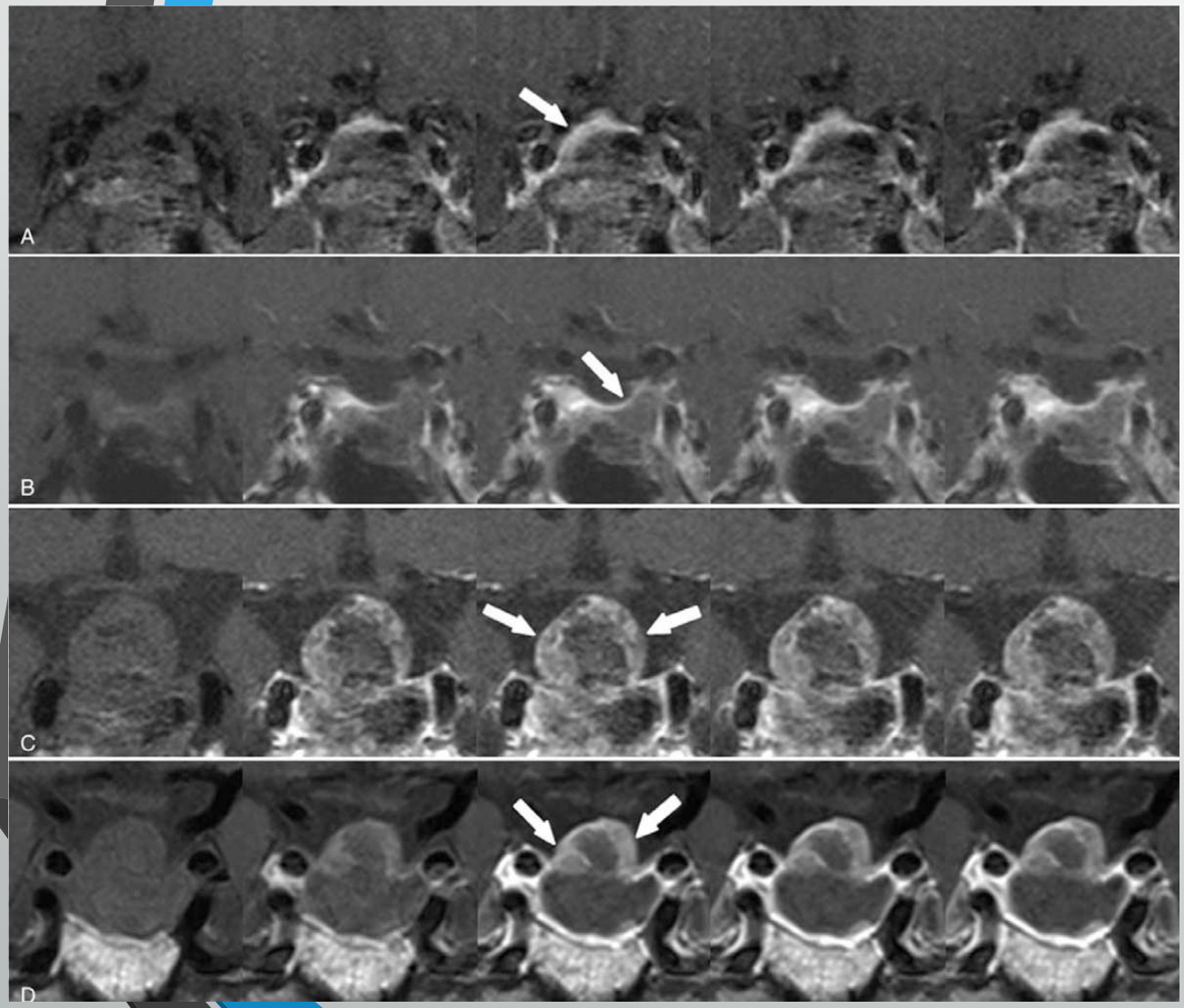

- Peripheral enhancement pattern. A 44-yr-old woman with histologically confirmed pituitary adenoma. Dynamic contrast-enhanced coronal images obtained within 48 h after surgery showed (a) a residual enhancing lesion with a peripheral pattern (arrow) in the postoperative tumor bed. Dynamic-enhanced coronal images obtained 5 mo later (b) revealed involution of the enhancing lesion. A 71-yr-old man with histologically confirmed pituitary adenoma. Dynamic contrast-enhanced coronal images obtained 48 h after surgery showed (c) a residual enhancing lesion with a peripheral pattern (arrow) in the postoperative tumor bed. Dynamic-enhanced coronal images obtained 11 mo later (d) revealed persistent enhancing lesion, indicating residual tumor.

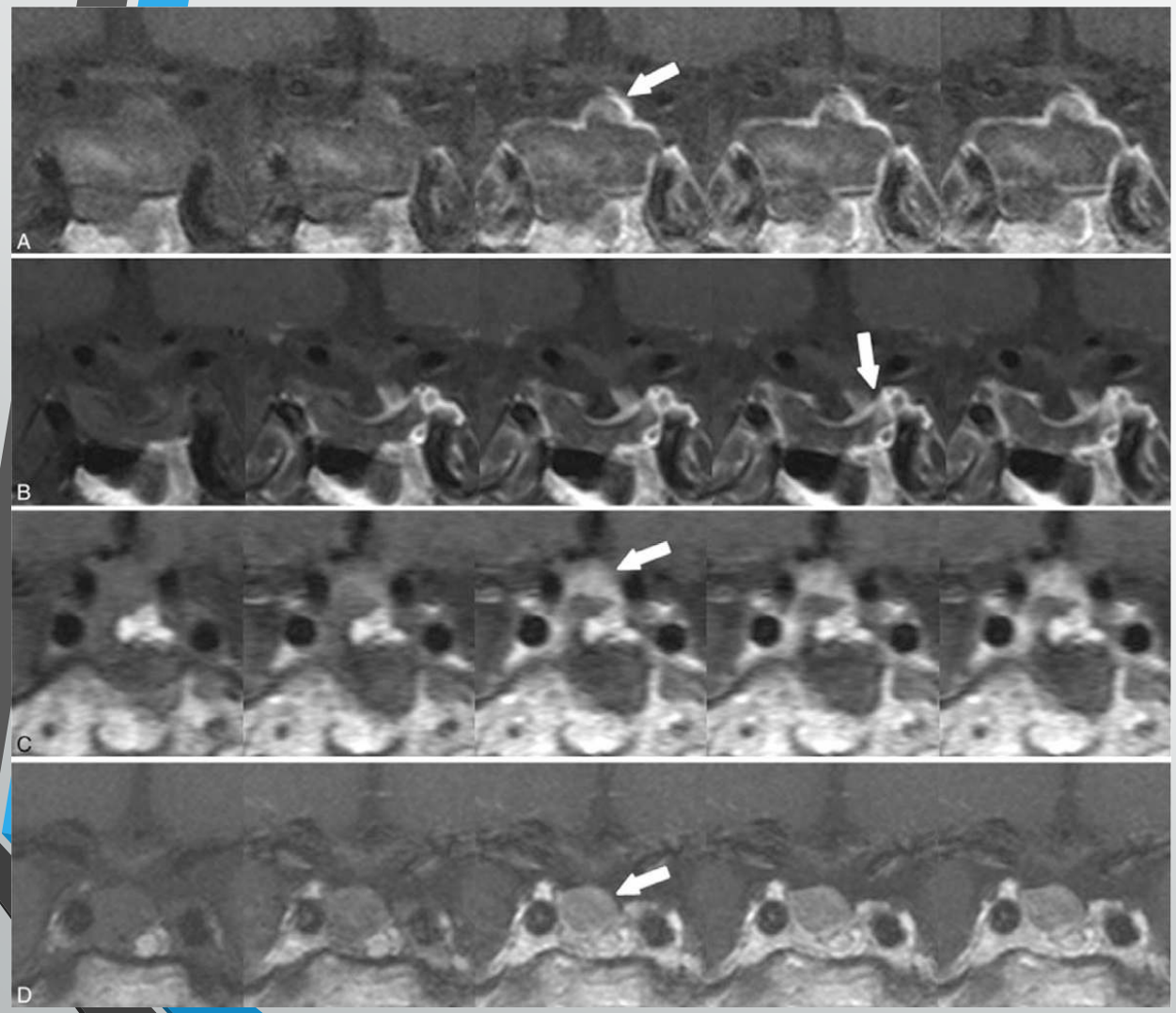

- Nodular enhancement pattern. A 73-yr-old man with histologically confirmed pituitary adenoma. Dynamic contrast-enhanced coronal images obtained within 48 h after surgery showed (a) a residual enhancing lesion with a nodular pattern (arrow) in the postoperative tumor bed. Dynamic-enhanced coronal images obtained 16 mo later (b) revealed involution of the enhancing lesion. A 68-yr-old woman with histologically confirmed pituitary adenoma. Dynamic contrast-enhanced coronal images obtained within 48 h after surgery showed (c) a residual enhancing lesion with a nodular pattern (arrow) in the postoperative tumor bed. Dynamic-enhanced coronal images obtained 15 mo later (d) revealed a growing enhancing lesion, indicating residual tumor.

THANKS FOR YOUR ATTENTION